

BREAKTHROUGHS IN INTEGRATIVE HEALING

A HEALTHCARE CHALLENGE

A NEW PARADIGM

Presented by

Gerald H. Smith, DDS, DNM, IMD, DHM

JUNE 25, 2020

Even though there have been major technological advances in medicine and dentistry both professions practice with a Neanderthal mentality!



NEW BOOK RELEASE

Remove the “Splinters” and Watch the Body Heal

Defining the Real Cause of “Disease”
and How To Fix It Naturally



A Vibrational Medicine Approach to Healing the Body
Secrets of Life, Longevity, and Anti-Aging

Dr. Gerald H. Smith

In an era of medical deceit, telling
the truth is a revolutionary act!

Remove the “Splinters” and
Watch:

Facial pain, TMJ, cancer, auto-
immune diseases, Alzheimer’s, chronic
pain, migraines, bipolar disorder,
CHF, seizures, vertigo and many more
“diseases” **DISAPPEAR !**

E-book now available at www.ghsdoc.com

THE BOOK FOCUSES ON

Correct

Underlying

Reason

Error

**SEVERE ECZEMA
RESOLVED BY
REMOVING THE
“SPLINTERS”**

TRAPPED VACCINES

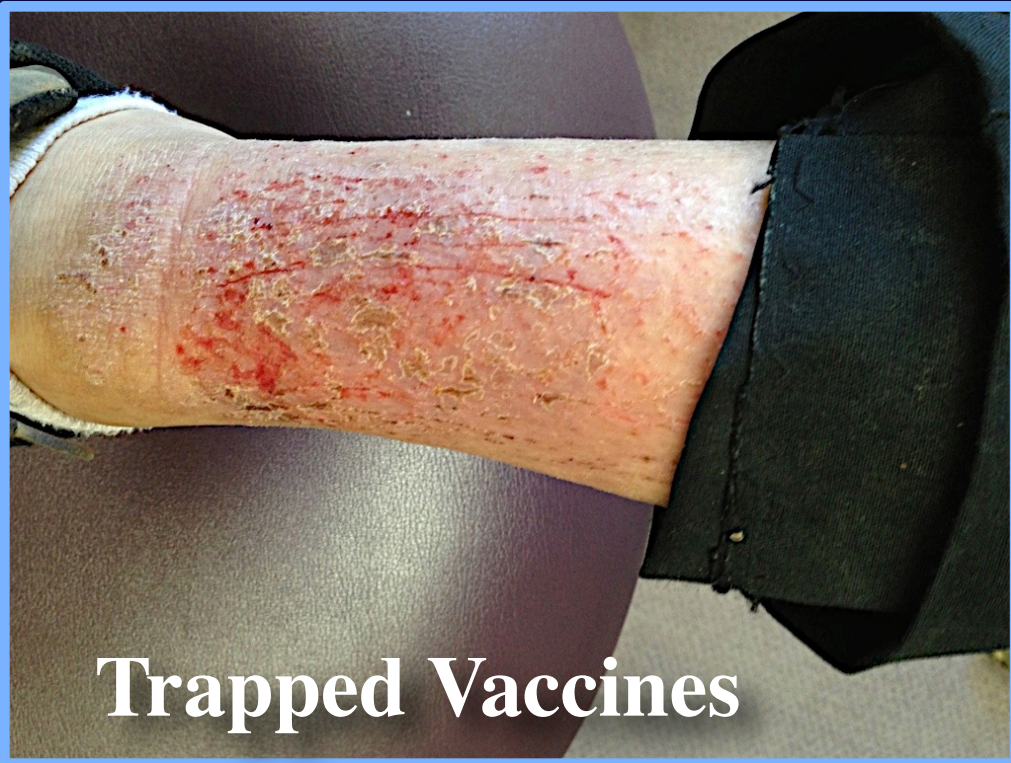

Severe Eczema

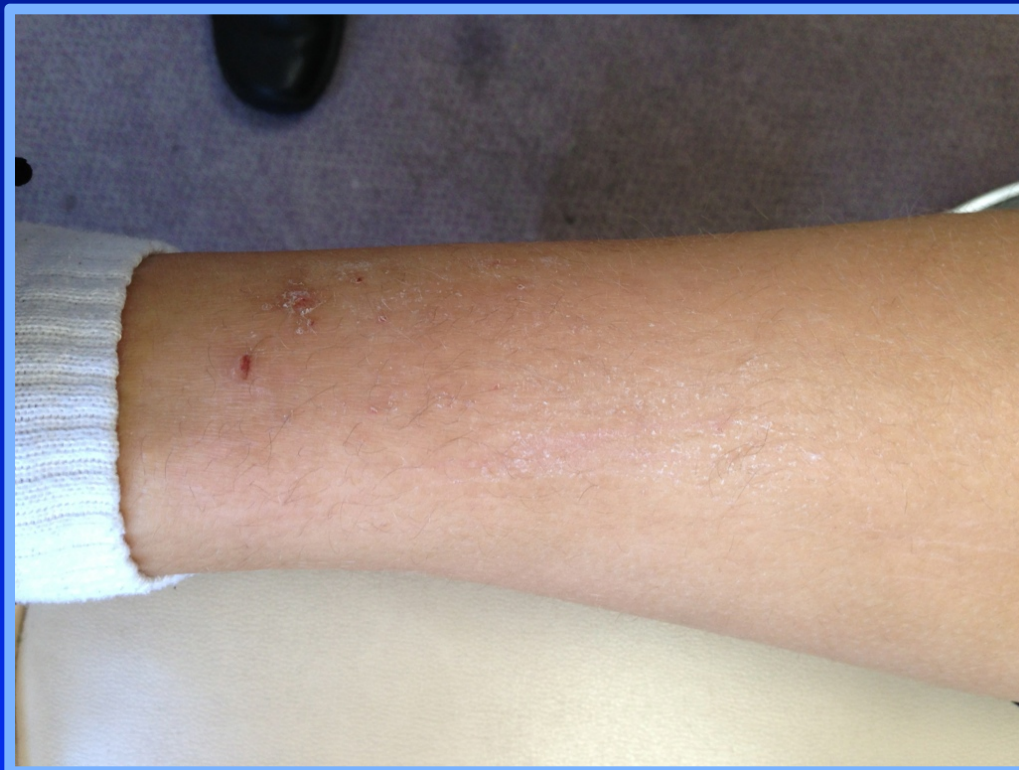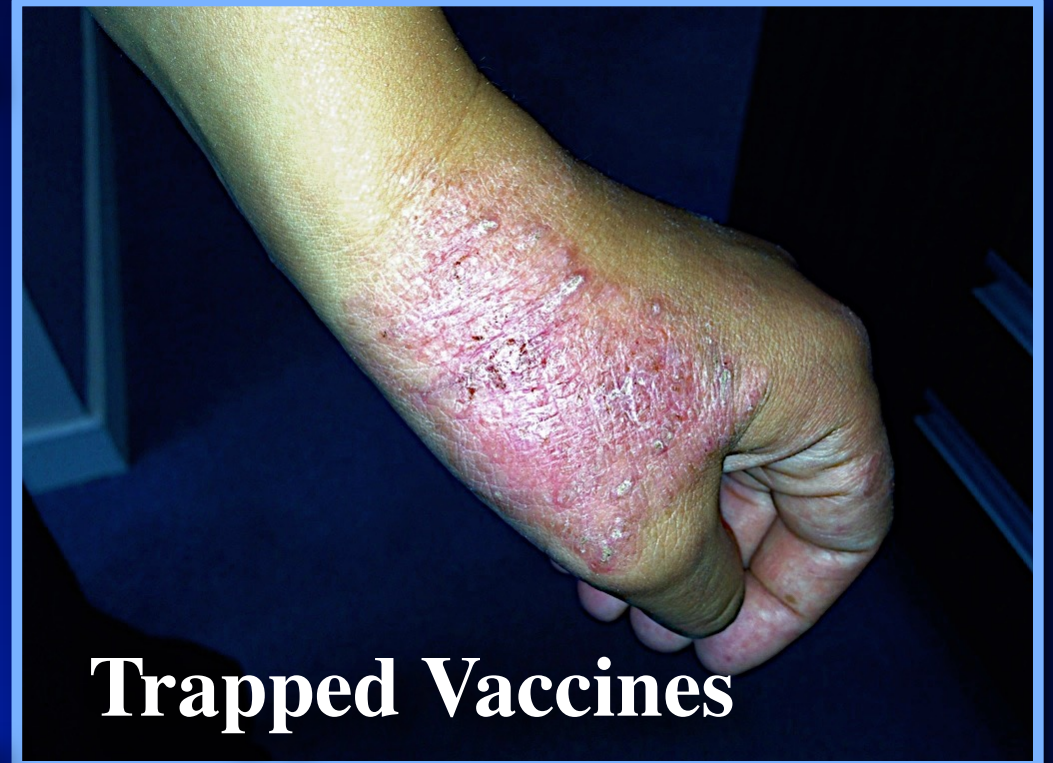Mervin is an 11 year-old Amish boy who suffered from severe eczema for several years. All conventional and alternative therapy failed to resolve the lesions. The core issues were never diagnosed:

- **Hypothyroidism**
- **Herpes Zoster**
- **Herpes Simplex I**
- **Cytomegalovirus**

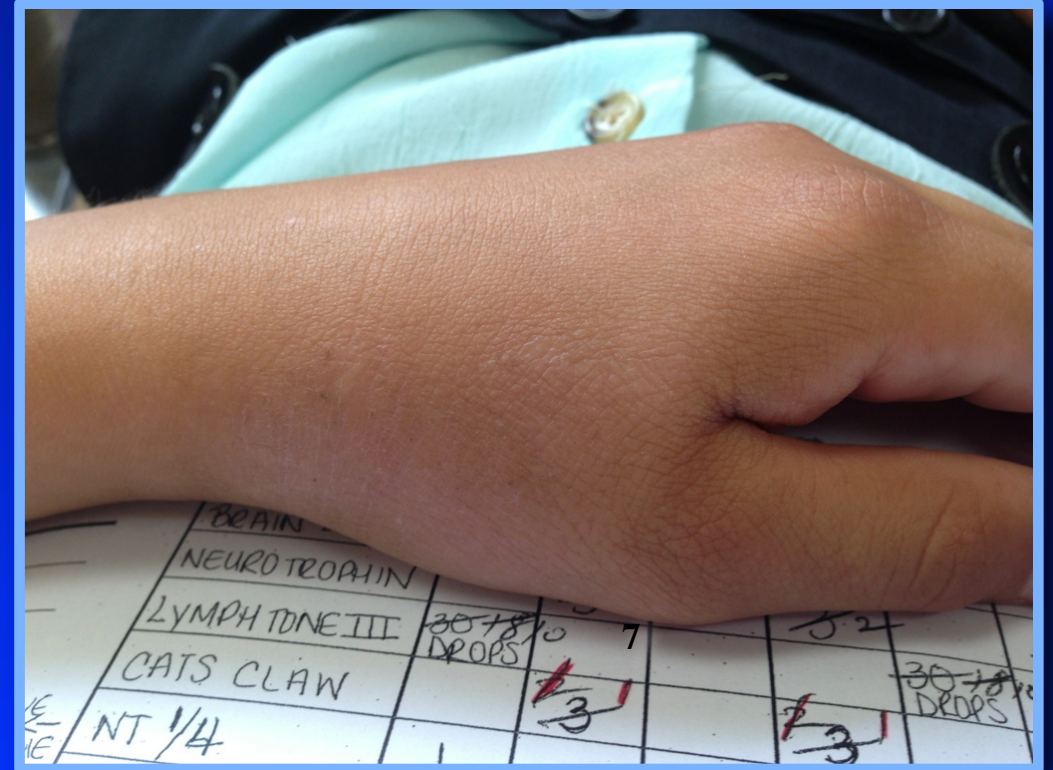HERPES ZOSTER/SIMPLEX/CMV



3 Months Tx
Nutritional
Support:
vitamins
herbs
homeopathics




Must use
food based
remedies
for
maximum
results



LIVER TRANSPLANT AVERTED

LIVER TRANSPLANT AVERTED



9.5 years ago Fred Schmidt was told he needed a liver transplant. His liver was swollen for 27 years and all of the high tech blood tests and other diagnostics could not diagnosis his problem. In one hour, the Quantum Testing Technique uncovered benzene and hepatitis B in his liver. Natural food based supplements were prescribed and seven months later all his liver enzymes and blood tests were normal.

Headaches

Centers for Disease Control

The prevalence of migraine headaches is high, affecting roughly 1 out of every 7 Americans annually. The key to resolving headaches is to define the root cause(s) and remove them.

HEADACHES CAUSED BY POST-CONCUSSION AND WHIPLASH

20 YEARS MIGRAINE HEADACHES

Medical History:

Two concussions

Three whiplash
injuries

Cranial adjustment:

December 2015

Alcohol was a
trigger for her
migraines



Patient has not had
a recurrence in her
migraines since
2015.

Concussion



In 1995 Andy was at a hockey game. Two players crashed into a glass panel at rink side knocking it out of its support rails. The glass did not break but it hit Andy in the head. He was unable to work for 4.5 months. He suffered headaches (level 3 or higher) every day for the past 21.9 years. He could tell you when it was going to rain two days before. When it rained he would crawl into bed in a dark room because the pain was excruciating.

He was seen by specialists at the Mayo Clinic, Johns Hopkins, U of P with no results. One cranial adjustment totally resolved his 21.9 year post-concussion symptoms.

Holly Paul

#1 US Women's Skeet Shooter



Medical History: Severe migraines for over one year. Feel on ice and hit the back of her head. She has no recollection of the 15 minute period when she was unconscious.

Past Medical Treatment: She was given every pain killer on the market plus steroids. Last proposed Tx was to put her under general anesthesia. Doctors had no explanation for the pain.

Diagnosis: Sutural jamming with cranial distortions.

Cranial Tx: Four cranial manipulations resolved the head pain.

Holly Paul

#1 US Women's Skeet Shooter

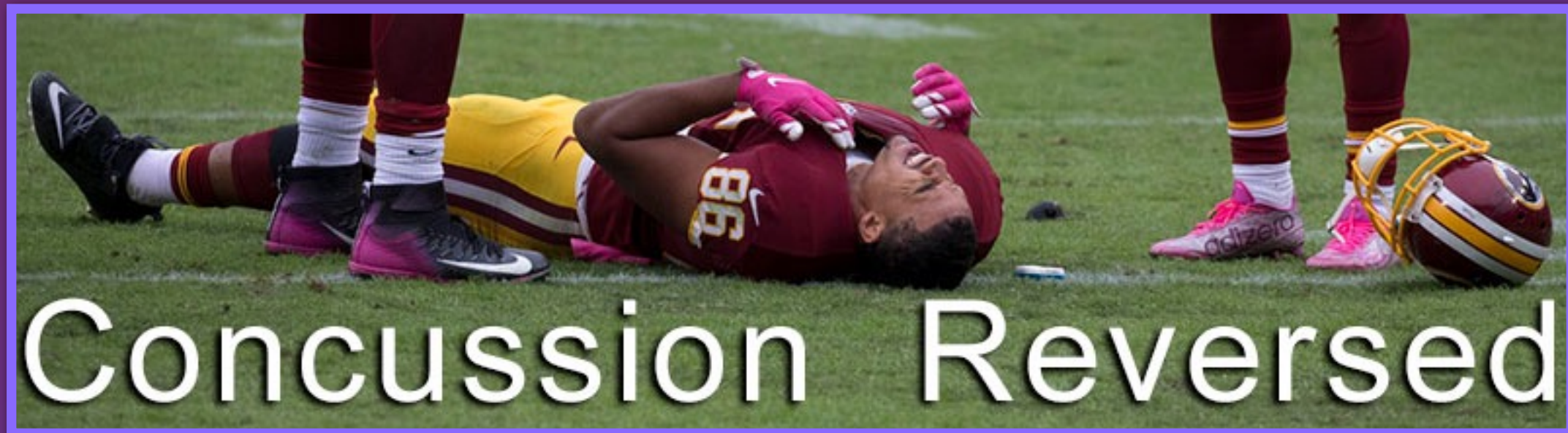

Recent Medical History: Pains in both thighs. Contemplating canceling national meet in Tennessee.

Proposed Medical Diagnostics: Doctors had no explanation for the pain but recommended taking a biopsy of the muscles.

Direct Resonance Testing: Cytomegalovirus, herpes simplex virus and lead poisoning.

Treatment: Rife frequencies for viruses and I.V. chelation for lead. Pain totally resolved.




ConcussionReversed.Com

- Eleven case reports with testimonials
- Articles and Interviews

MERCURY INDUCED MIGRAINES

Dental Migraine Connection



Patient: R.C.

Age: 58-year-old

Date: December 11, 2000

Occupation: Teacher

Chief Complaints: Migraine headaches for past 25 years.

Treatment: Removal of all mercury fillings.

Results: Migraine headaches completely resolved one month after removal.

Polycythemia Vera Dental Connection



Patient: Richard J. Minicozzi, MD

Age: 67-year-old

Date: December 23, 1998

Occupation: Medical Doctor

Dx: Mercury poisoning, cranial distortions and lost vertical

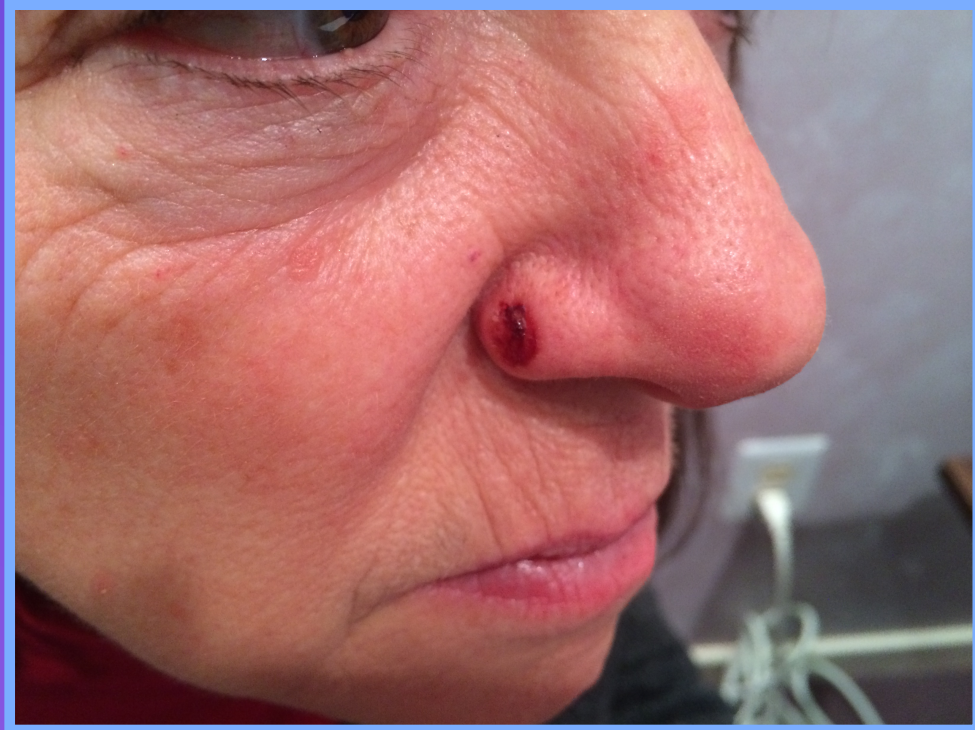Chief Complaints:

1. Frequent headaches
2. Pain in upper jaw
3. Reduction in visual brightness
4. Heaviness of legs
5. Neck and low back pain
6. Dizziness
7. Reduced hearing
8. Stomach pain

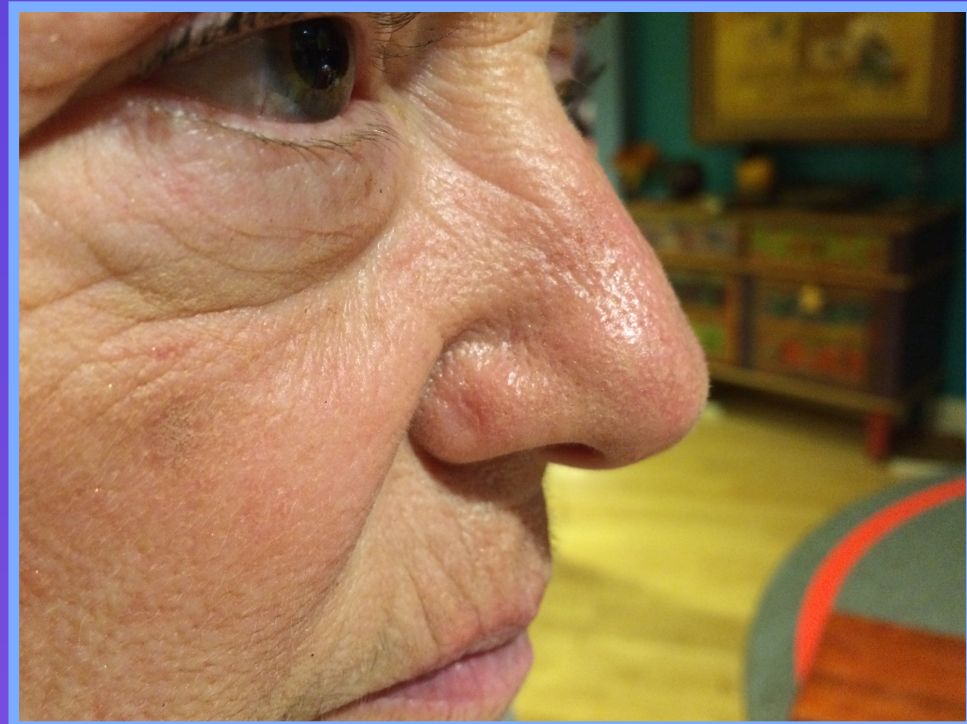Basal Cell Carcinoma Mercury Cancer Connection

CyberScan Professional System

Does scalar frequency technology really work?



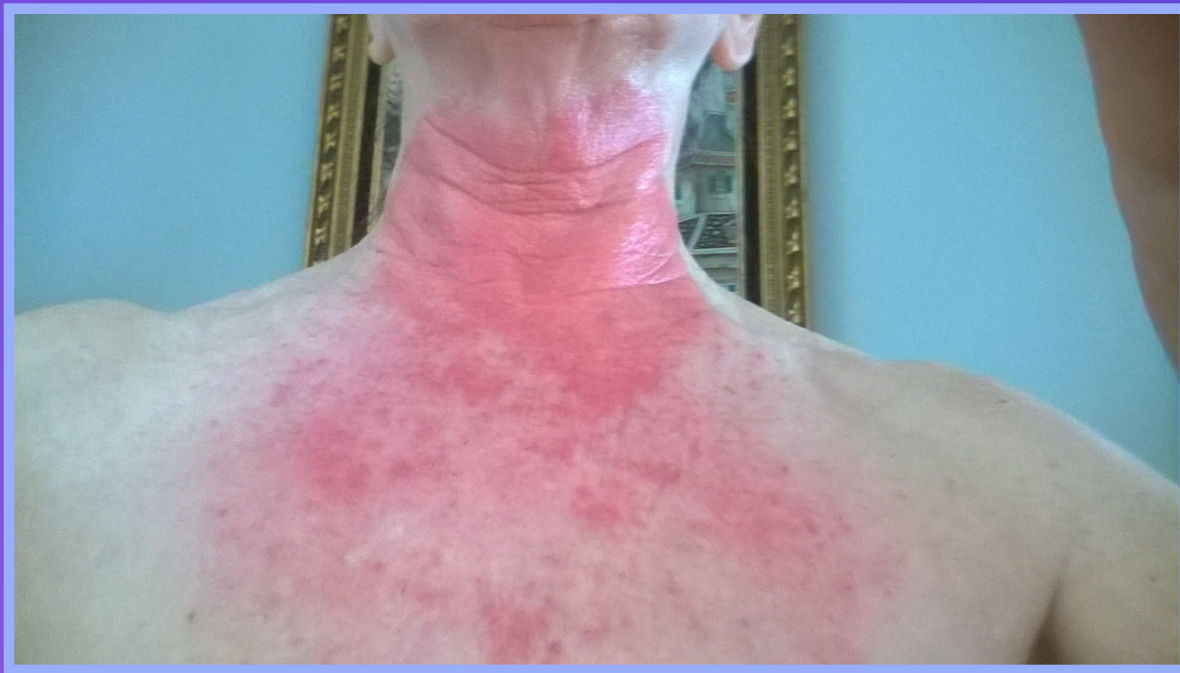*Basal Cell Carcinoma
Pre-Tx*



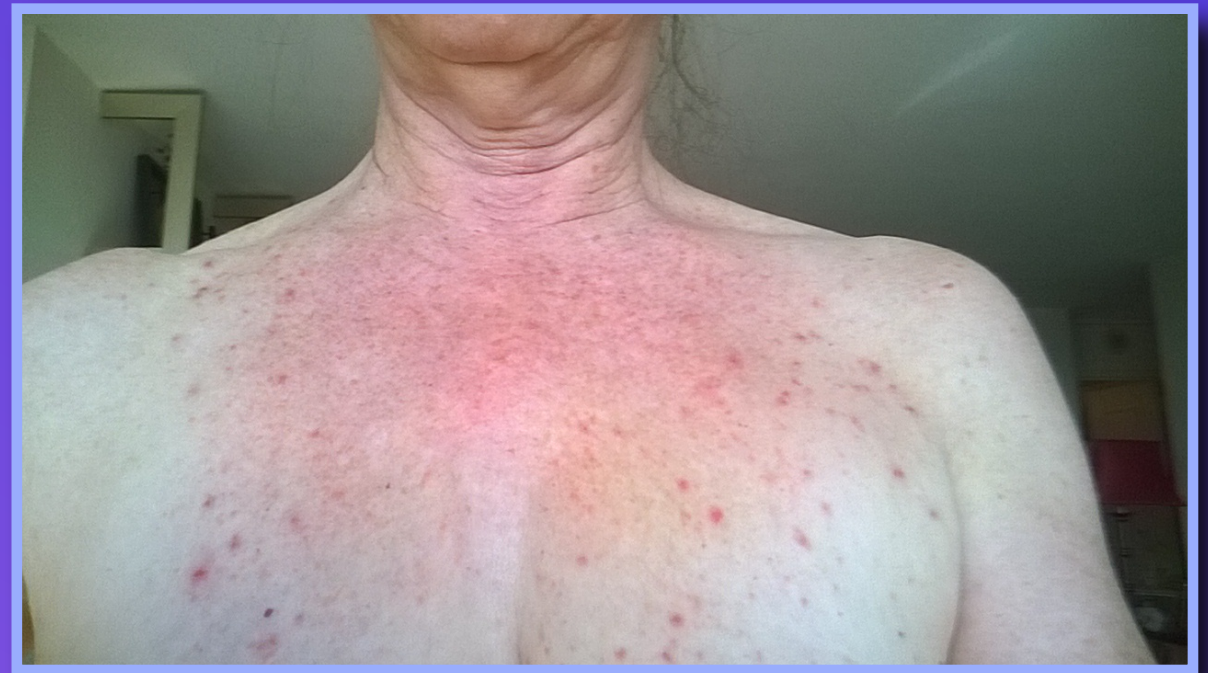*Basal Cell Carcinoma
1 year Post-Tx CyberScan
and nutritional therapy*

CyberScan Professional System

Detox reaction from CyberScan Tx and supplements



Mercury detoxing from thyroid



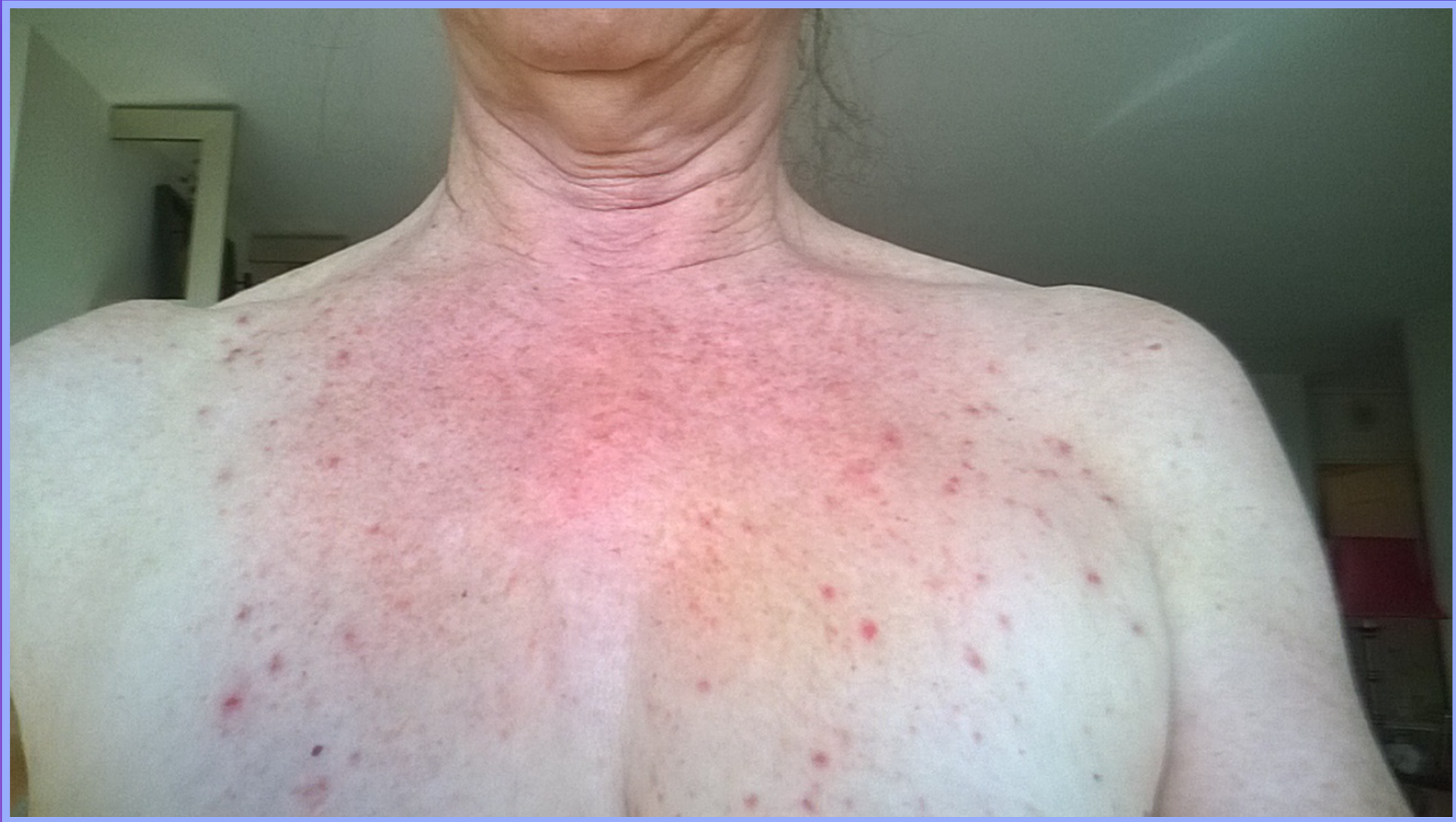Later stage of detox

**Mercury was present in the basal cell lesion as well
as many other toxins.**

CyberScan Professional System

Detox Reaction From Supplements

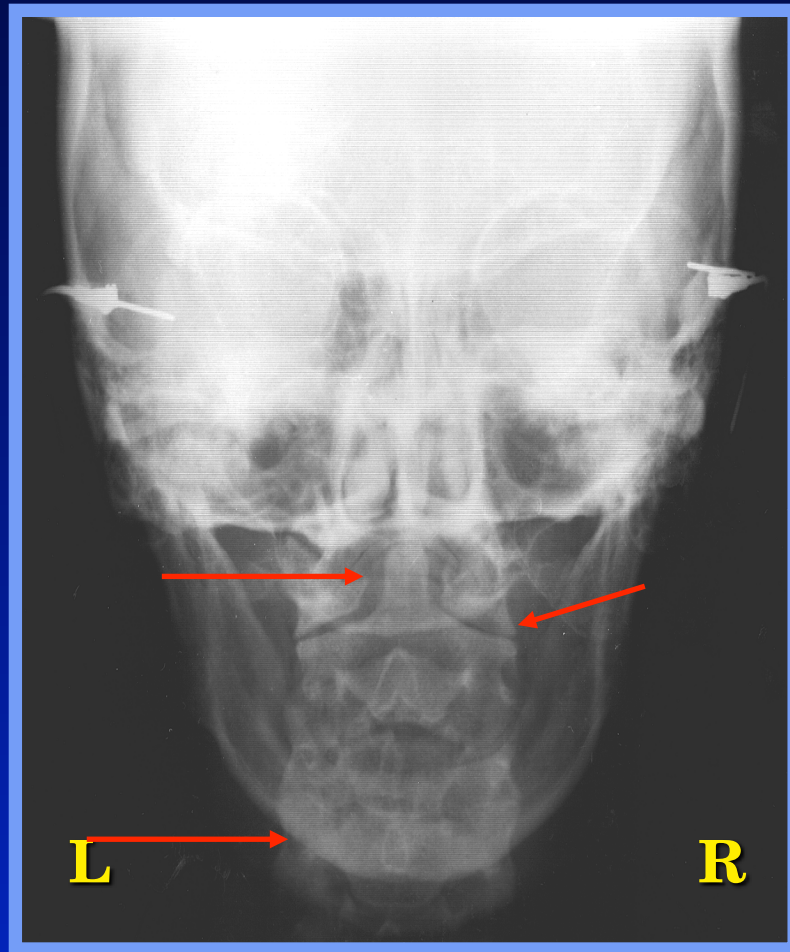
Third stage of detox



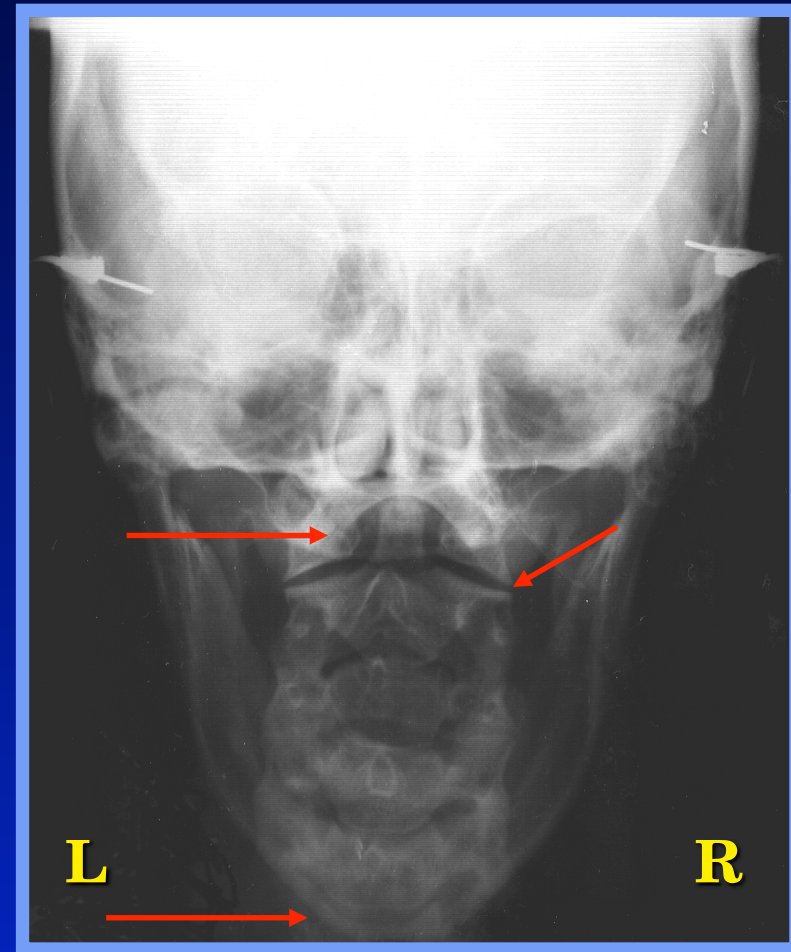
Chief complaint was severe itching due to toxins exiting the body (candida, pesticides, heavy metals, vaccines, etc.)

TRAUMA INDUCED MIGRAINES

Mattie Stoltzfus



Pre-Tx 9/30/97

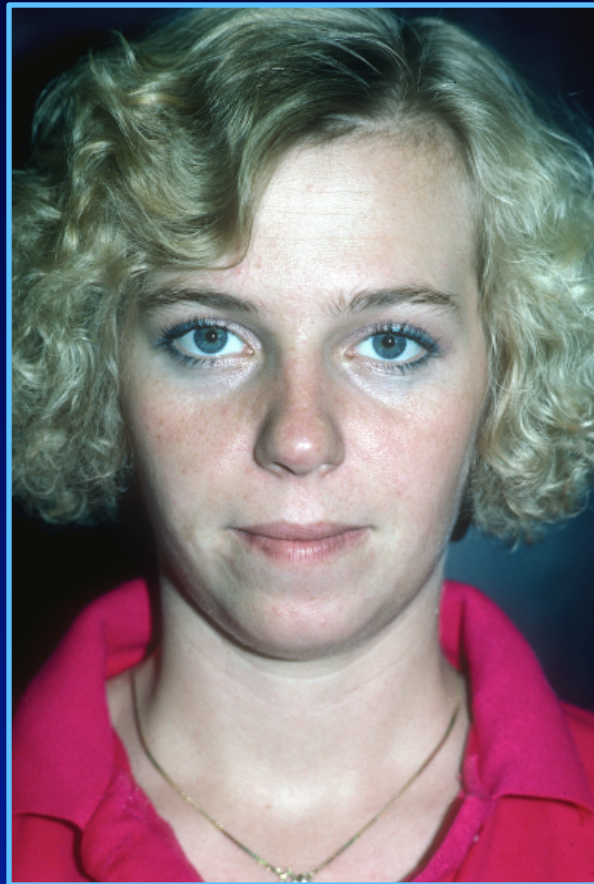

Post-Tx 9/30/97

35 years of headaches and three years of right thigh pain resolved by a cranial adjustment- one hour post-Tx x-ray.

ORTHODONTIC TREATMENT INDUCED CHRONIC HEADACHES

Cranial Major



Patient: Astra Czerny

Age: 23-years old

Date: 9/21/85

Chief Complaints:

Chronic headaches

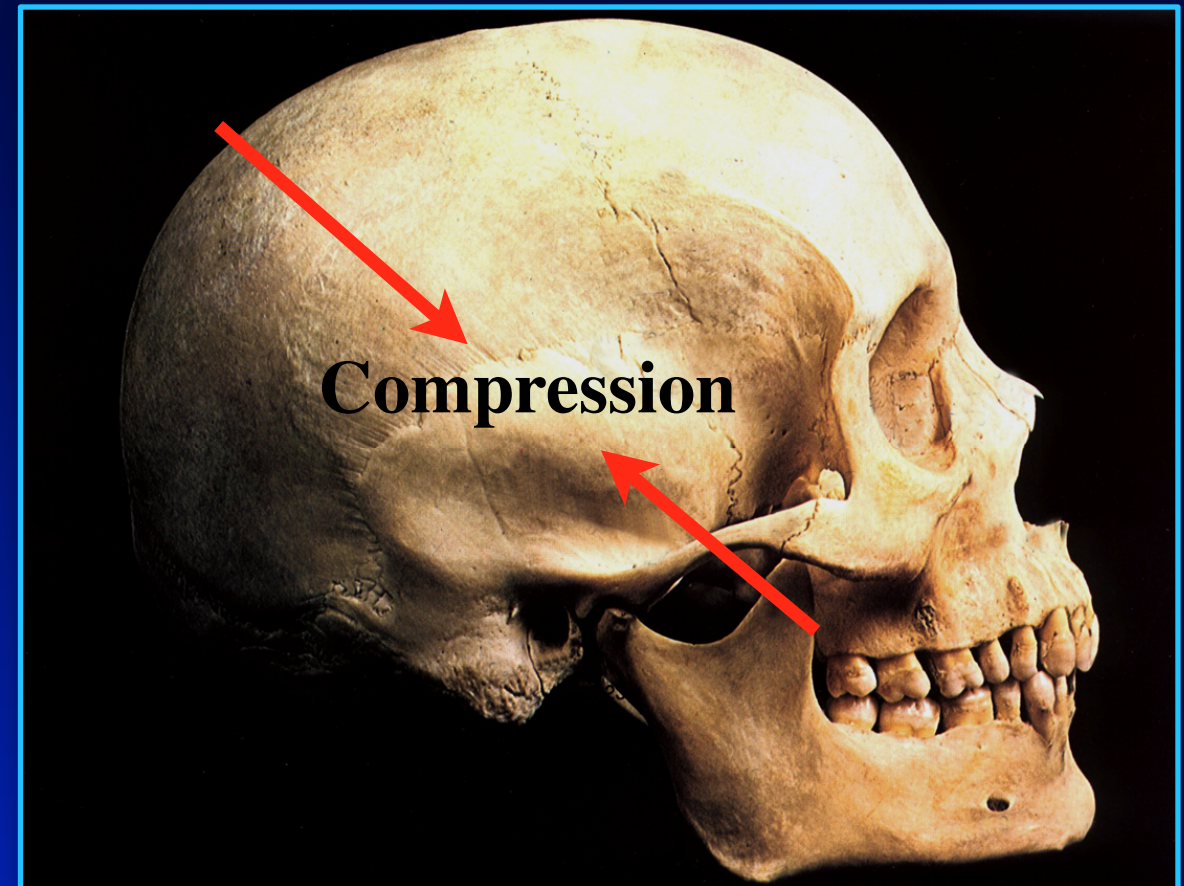
Left TMJ pain

Dx: Jammed cranial sutures

Tx: Cranial manipulation

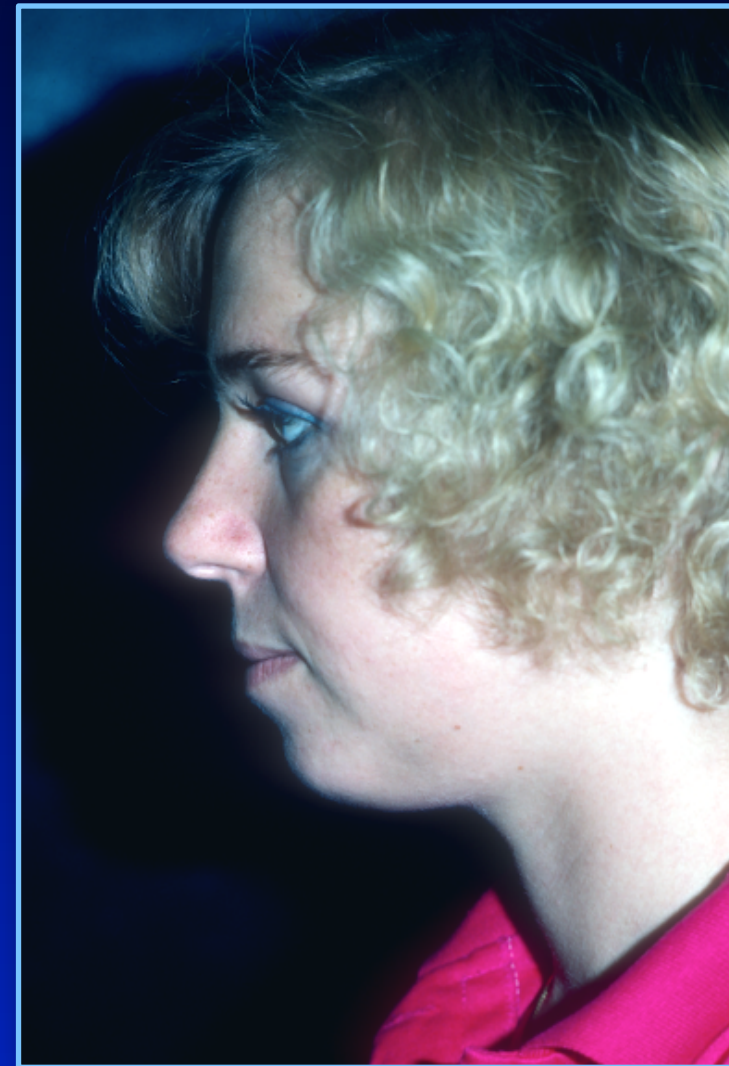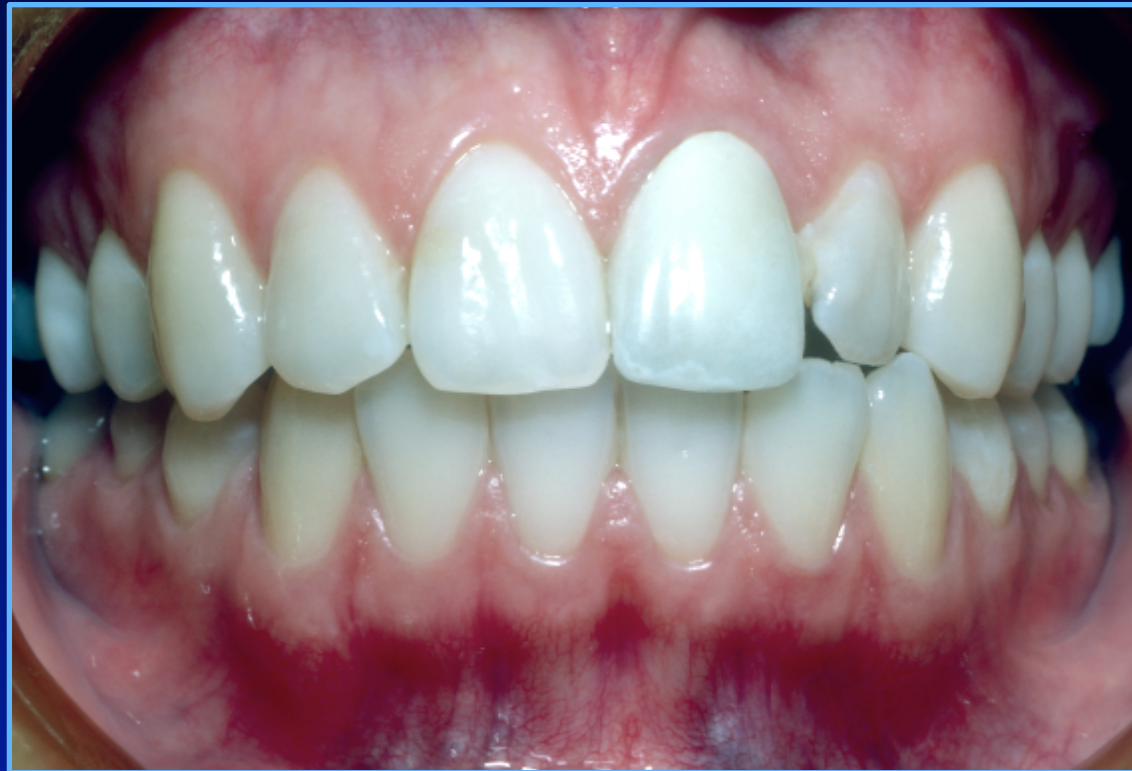Medical /Dental History: Patient had conventional orthodontics with high-pull headgear. Headaches were constant. Aspirin taken every day for pain. Patient had been to many major international headache clinics with no results. Patient told doctors that when she walked to school she would press her books down on top of her head and the pain would disappear.

High-Pull Headgear



Headgear is used for anchorage while the upper buccal segments are being retracted. “Moderate-force” loads applied in the range of 500-750 grams. One ounce equals 28.35 grams - 625 grams = 1.377 pounds pressure for a three-to four-month period. What effect will this have in deforming the skull bones, sutures and dural membrane system?


Cranial Major



The occlusion was stable and not a factor in the pain equation. Since cranial sutures are viable structures imbedded with nerves, blood vessels, lymphatics, sharpe's fibers and connective tissue, compression will trigger anoxia and pain plus distort the dura.

HORMONE IMBALANCE INDUCED MIGRAINE HEADACHES

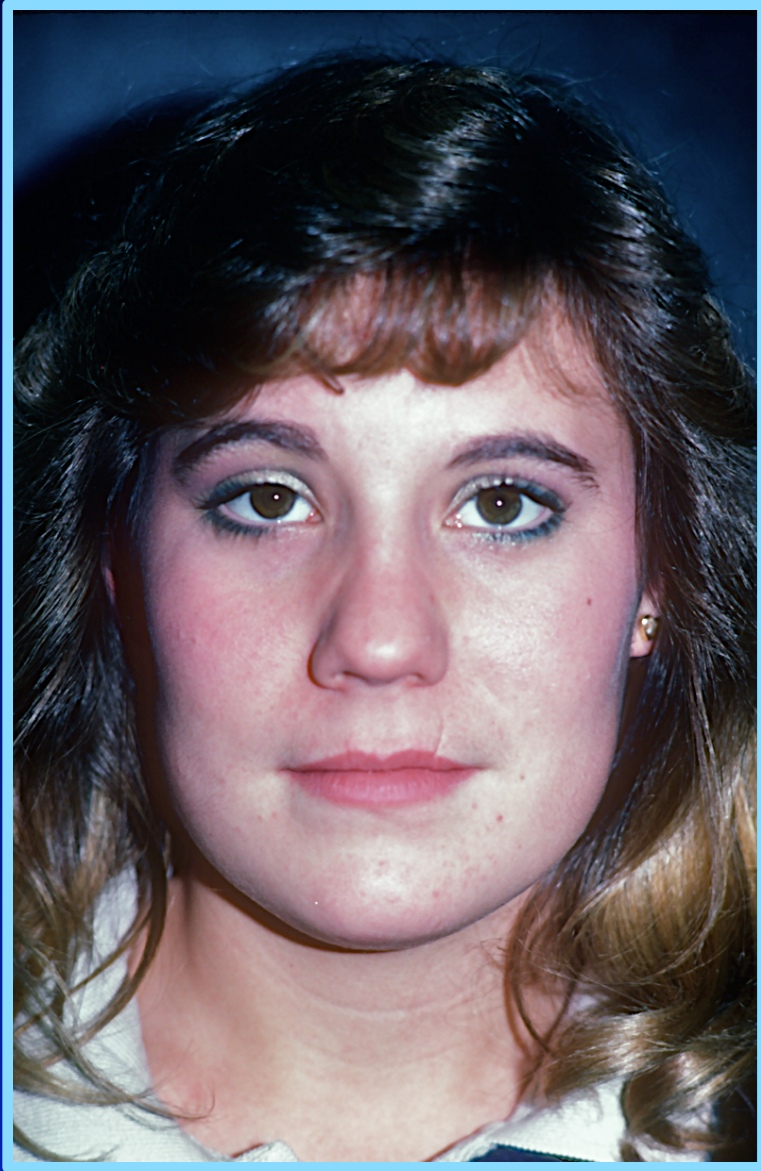Menstrual Migraines



Heather Kennedy was incapacitated for two weeks out of every month because of menstrual migraines. She had a chronic abscessed tooth, which directly affected her thyroid and hormone balance. Once the infected tooth was removed and nutritional support provided for her thyroid, her migraine headaches totally disappeared.

VITAMIN DEFICIENCY INDUCED HEADACHES

Amy Cubberly



Age: 18 years-old

Date: December 1987

Chief Complaints:

Chronic headaches for past 13 (since 5) years:

- Throbbing type
- Can occur any time night or day
- Does not awaken patient during sleep

Headaches set off by:

- Ice cream
- MSG
- Increased consumption of refined carbohydrates (mainly sweets)

Amy Cubberly



Age: 18 years-old

Date: December 1987

Dental History:

Orthodontic Tx: 4 bicuspids extracted

Cranial Findings:

- Sphenoid: low on left
- Maxillae: canted upward on left
- Mastoids: neutral position
- SBS: left sidebend
- Amplitude: restricted on left

Clinical Findings: Bilateral spasm of external pterygoids

Has seen all medical headache specialists

Amy Cubberly

Treatment:

- Myofascial release of external pterygoids
- Cranial manipulation
- Nutritional support
 - Cataplex B: assists in carbohydrate digestion
 - Cataplex G: assists in carbohydrate digestion- fats
 - Black Currant seed oil: helps balance hormones

Results: Headaches disappeared after two weeks.

SURGICALLY INDUCED FACIAL AND NECK PAIN, PARESTHESIA, AND BITE MISALIGNMENT

24 Years Facial Pain

Judith Hagan

Medical History

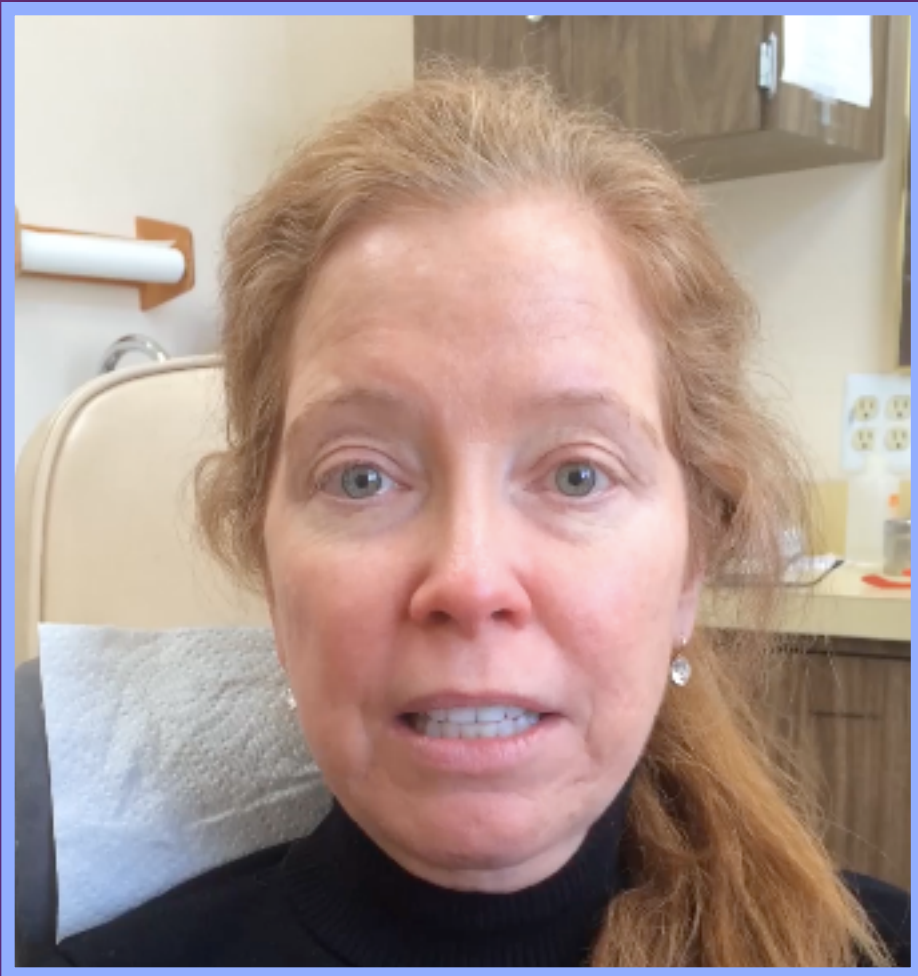Twenty-four years ago, Judith Hagan underwent a surgical procedure to remove a cholesteatoma (benign bone tumor) from her right ear. The surgery was a success however it left Judith with facial pain, paresthesia, and the inability to close her teeth comfortably.

“Modern” Dental/Medical Technology is based on Neanderthal Mentality.

24 Years Facial Pain

Treatment

A comprehensive cranial adjustment corrected her post-surgical skull distortions and her 24 years of facial pain, paraesthesia, neck pain, and bite misalignment disappeared immediately.



Judith Hagan

DENTALLY INDUCED DEPRESSION

Dental/Whole Body Connection

DENTAL HISTORY

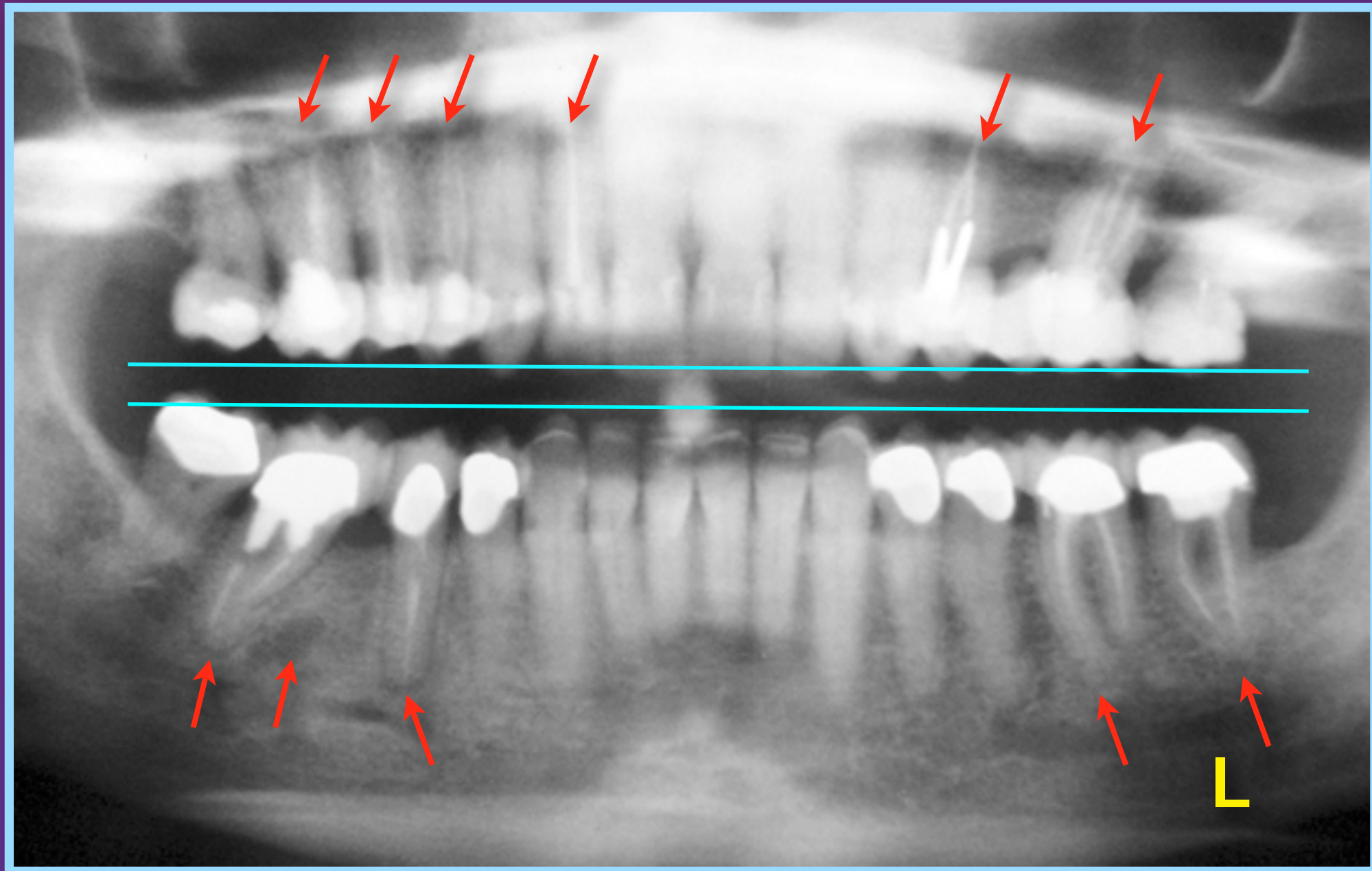


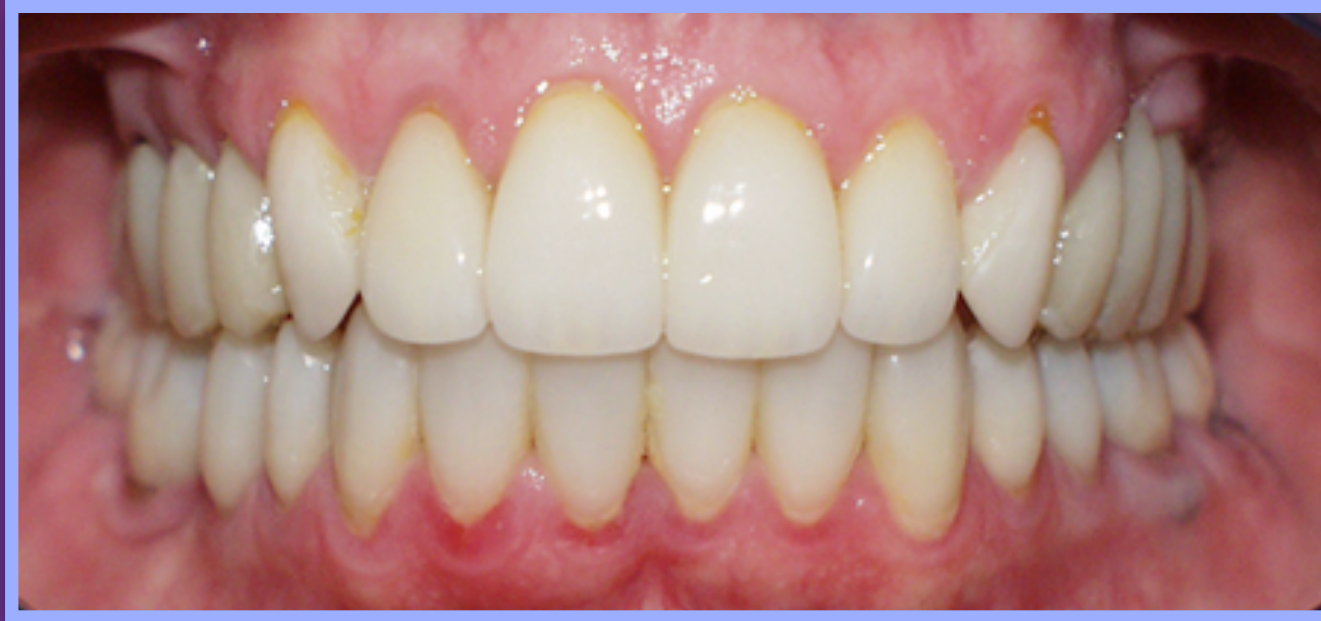Vicky Behrens

2005: FULL MOUTH REHABILITATION

2006: MULTIPLE SYMPTOMS
FACIAL PAIN/TEETH PAIN
NECK AND SHOULDER PAIN
BURNING OF GUMS AROUND
MAX ANTERIOR CROWNS
DEPRESSION, ANXIETY,
MENTAL FOG, CHOCKING
BITE UNCOMFORTABLE

All ten root canal teeth were infected !





Every structure in the mouth drains to the thyroid gland via the lymphatic system. Mercury fillings, root canal infections, toxic dental materials, and ingested food toxins ultimately get to the thyroid. This is one of the reasons why there is so much depression today.

ORAL PAIN

Uncommon Dental Issues

Ten Years of Sever Oral Pain



Oral Herpes Zoster

ATYPICAL FACIAL PAIN DENTAL CONNECTION

Linda Penzabene



Albano, Italy

Age: 52 years-old

Date: March 2006

PAR: Dental Major

Compensatory cranial
Sympathetic dominate

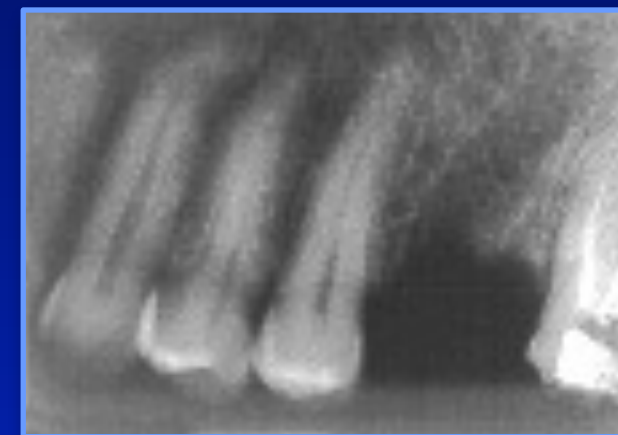
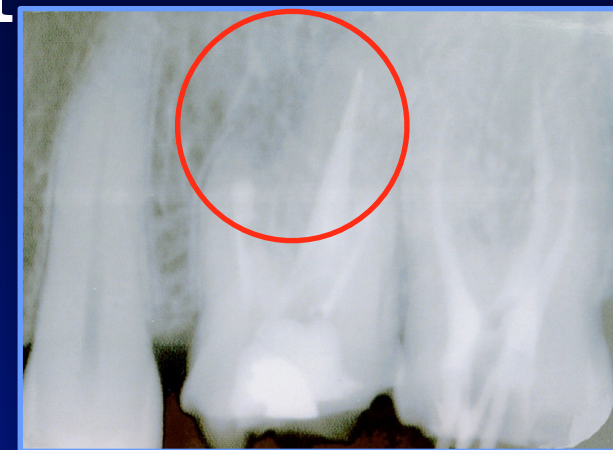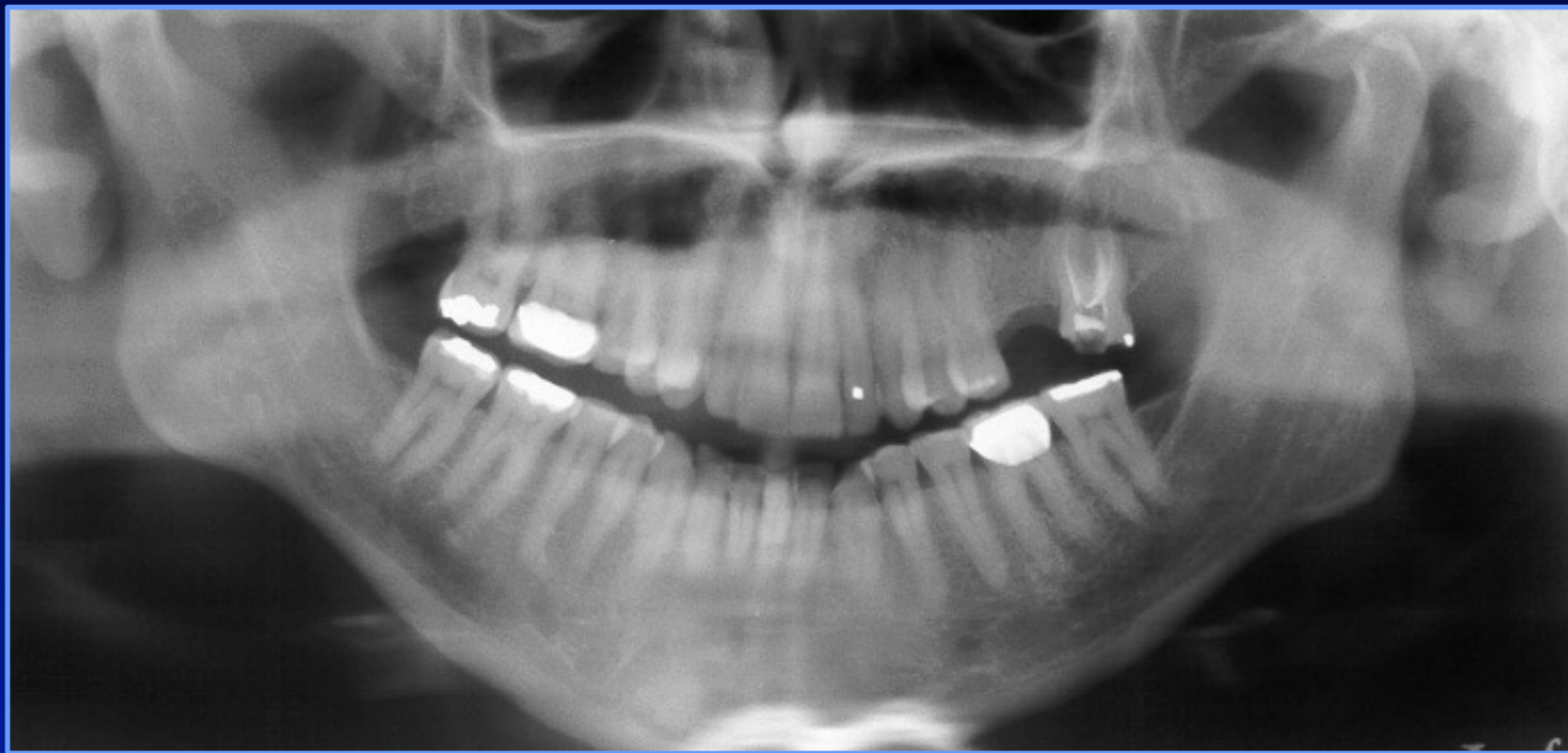
Chief Complaints: 4 months duration

1. Facial pain.

2. Tooth pain (maxillary right first bicuspids).

Pain started immediately after replacement of two resin restorations.

Atypical Facial Pain Dental Connection



Multiple root canal treatments were performed on the upper left first molar without success in resolving the pain. The tooth was extracted but the pain persisted for 2.5 years.

Dx: Staphylococcus, Streptococcus, osteomyelitis

Tx: Injected homeopathic remedies into extraction site and biofrequencies

Result: Pain totally resolved and pain free since 2009.

Treating Chronic Tooth Pain

Common Dental Issues

Medical/Dental History

C.C. Severe Facial Pain lower right mandibular area near canine.

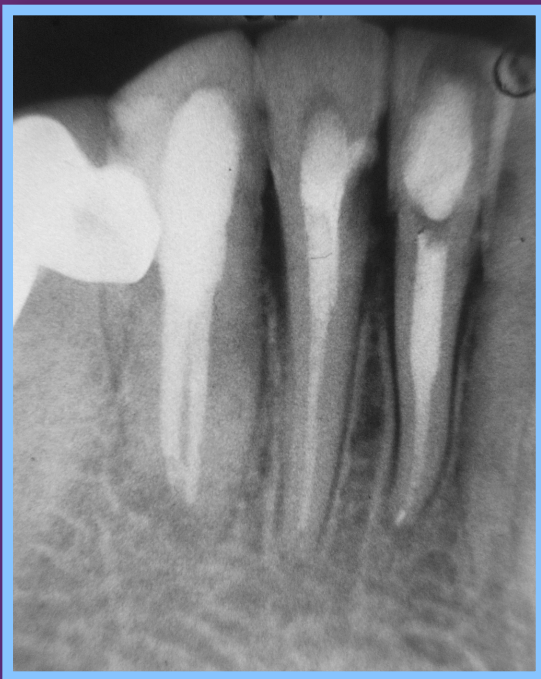- Nerve Blocks - #27 Failed
12/05 thru 3/06
- Root canal on #27- failed
- Root canal re-treatment- failed
- Apico- failed
- Ablation of mental nerve- Failed
- 4/06 Gamma knife- failed
- 9/06 Craniotomy (32 staples)-
failed



Dawn McMahon

Common Dental Issues

Dawn McMahon

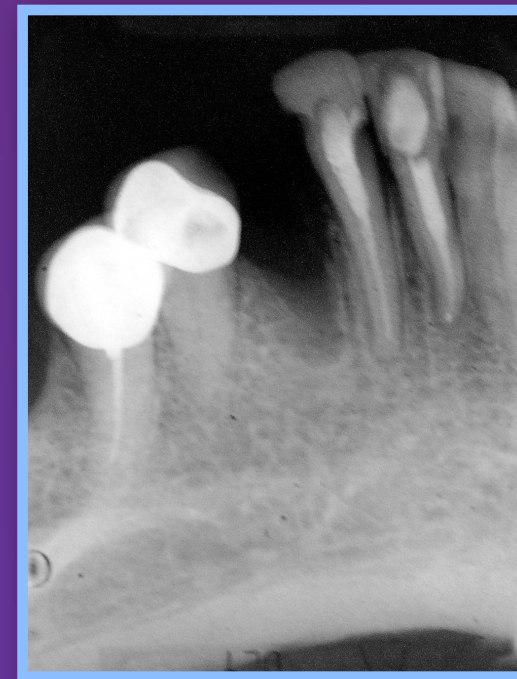

Medical/Dental History

C.C. Severe Facial Pain lower right mandibular area near canine.

Direct Resonance Testing:

- Herpes Zoster
- Herpes Simplex I



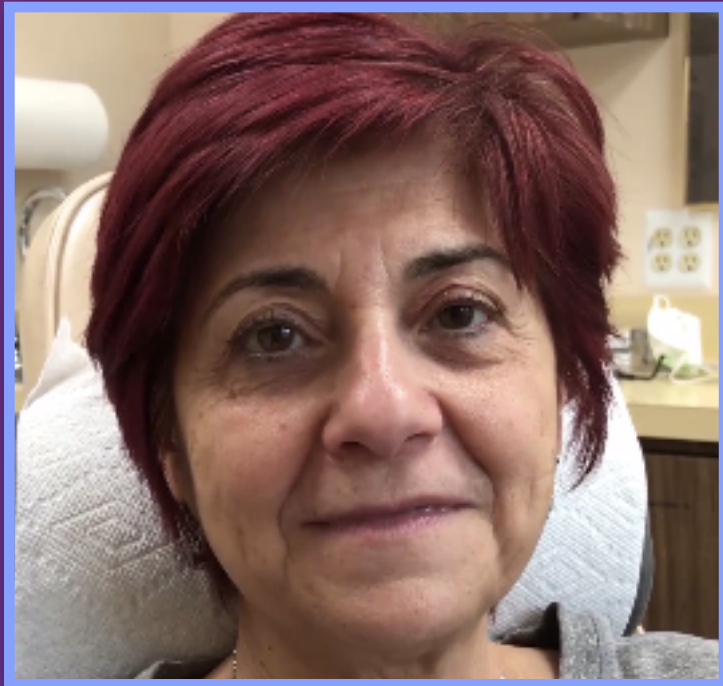“Modern” Dental Technology is based on Neanderthal Mentality.

Lung Cancer

Root Canal

Cancer Connection

CARCINOMA RIGHT LUNG

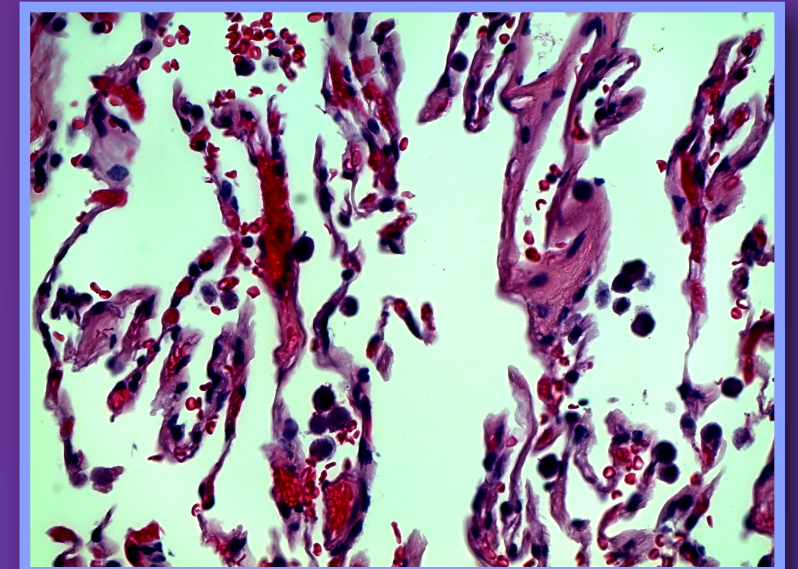
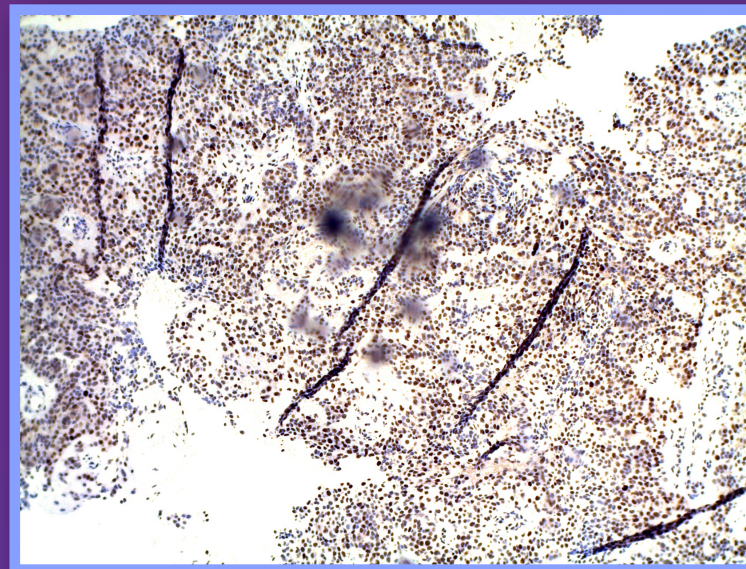
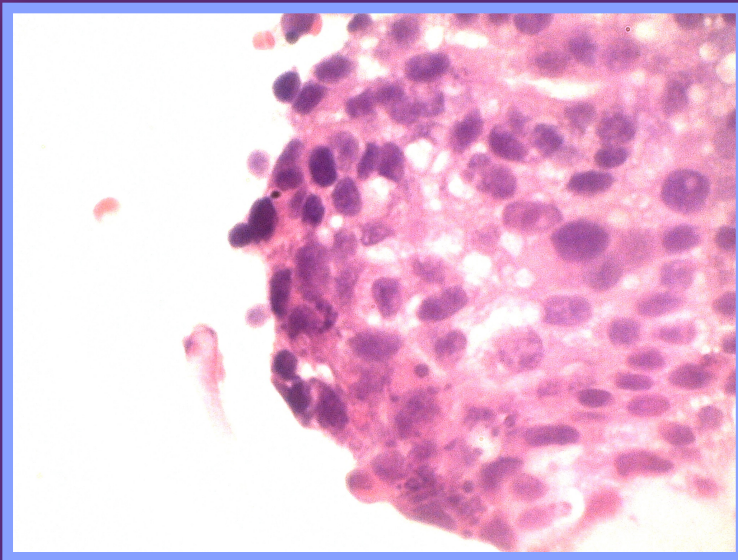
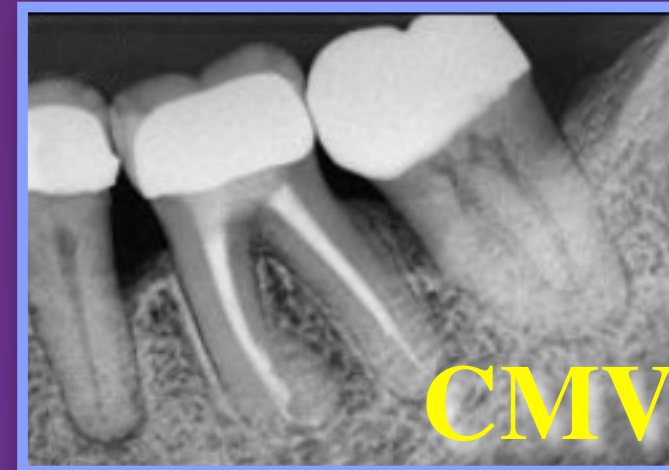


Carol K. developed right lung cancer. **Traditional Tx:** cut tip of right lung off where cancer was present. The patient refused chemo or any other Tx.

Six months later the cancer appeared in the left lung. Patient refused any surgical intervention. Carol was referred to my office by her chiropractor.

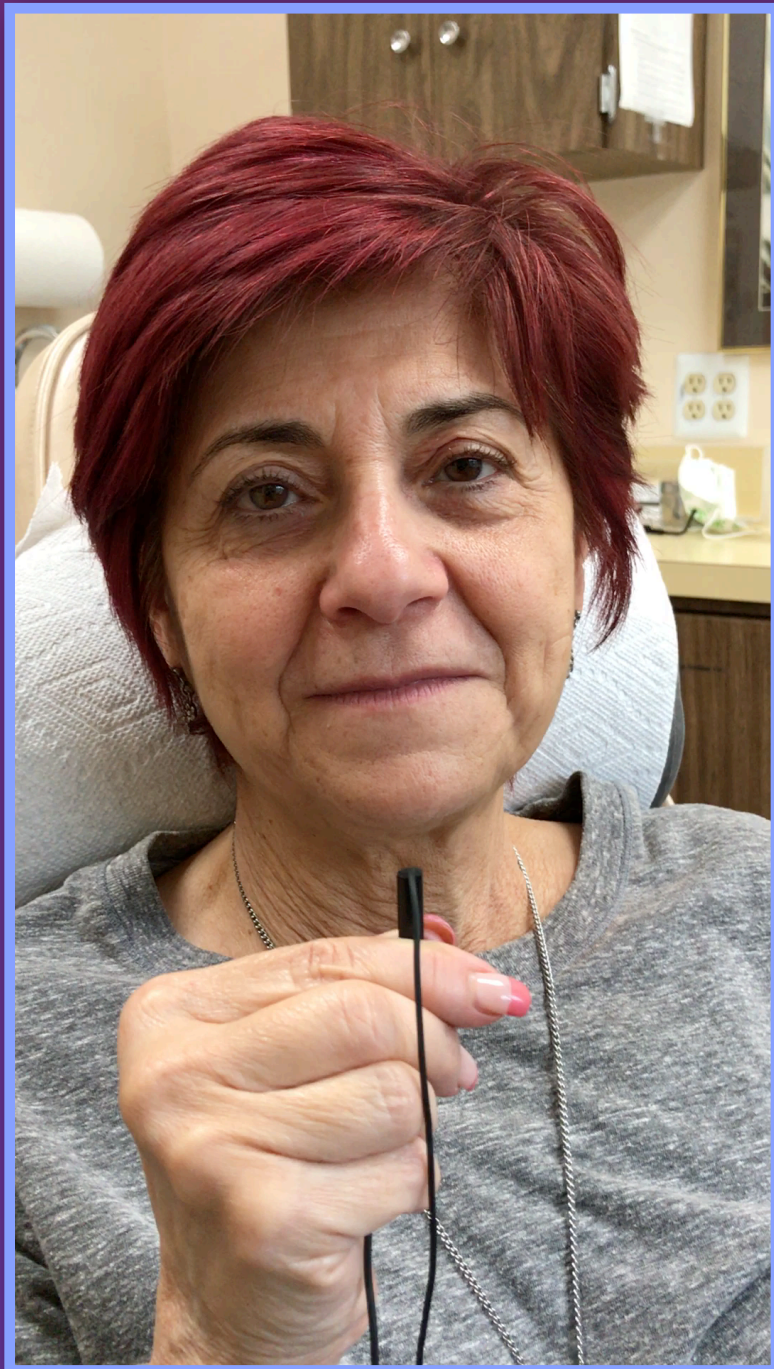LUNG CANCER

Pathology slides were
tested energetically



Quantum Testing Dx: CMV, Hg, and a pesticide in the
cancerous tissue!

LEFT LUNG CANCER



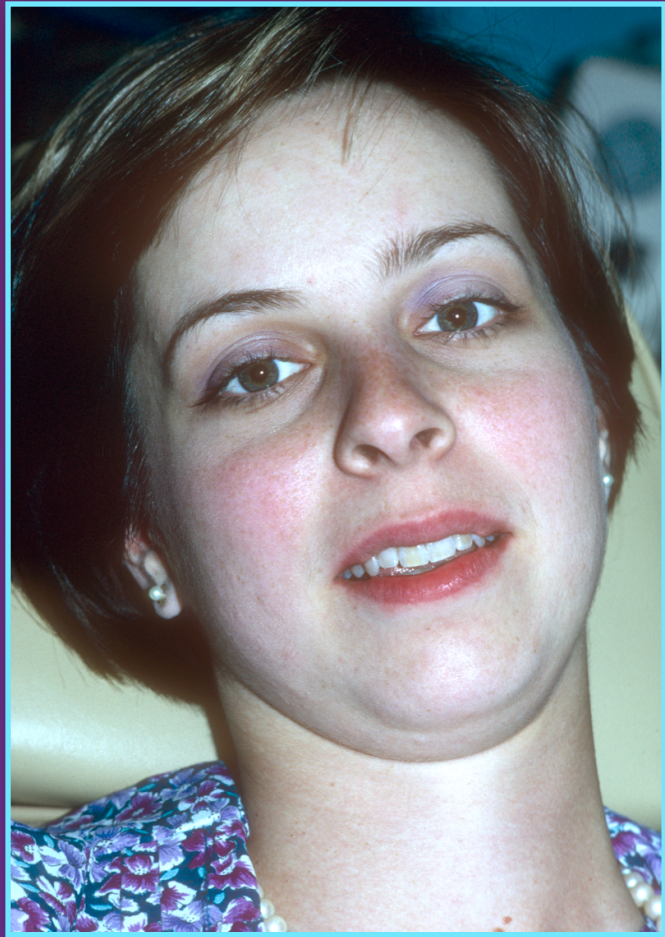Carol K. was placed on a nutritional program to detox her liver, open up drainage, chelate the Hg, pesticide, and remove the CMV. Also the mandibular left molar was extracted. Extraction site **Tx:** O₃, Ionic Ag, Sanum remedies that were tested compatible for the patient.

Additional Tx: Theraphi and CyberScan

The squamous cell carcinoma disappeared totally in six months.

**DENTAL
MALOCCLUSION
INDUCED HEADACHES
AND PETITE MAL
SEIZURES**

Dental Seizure Connection



Patient: P.M.

Age: 26 yrs old

Date: August 1984

C.C.: Chronic headaches, Petite mal seizures 2-3/wk

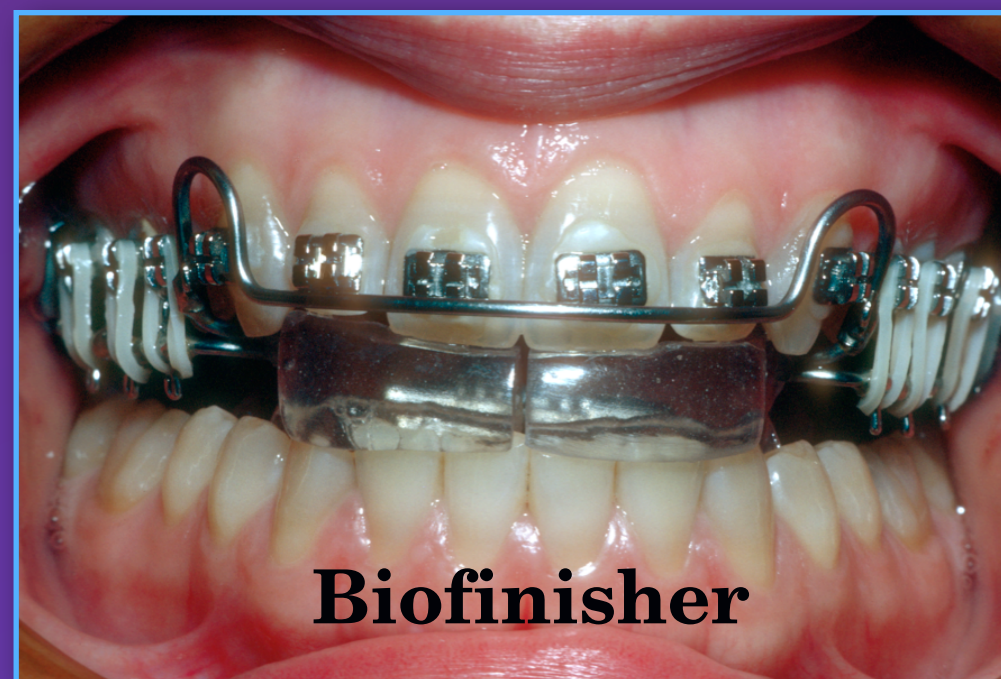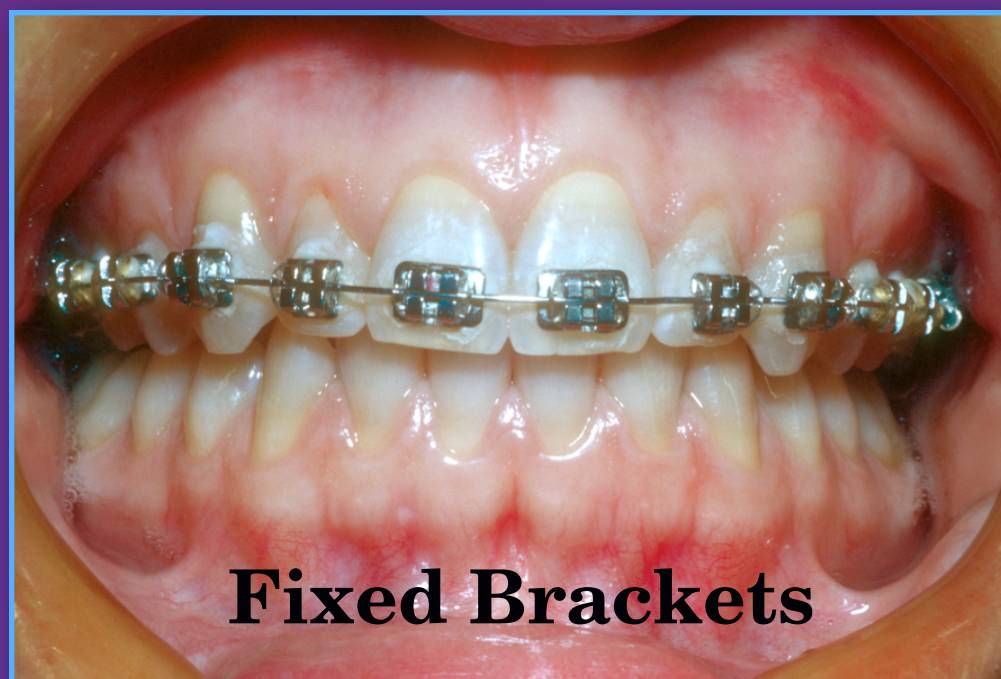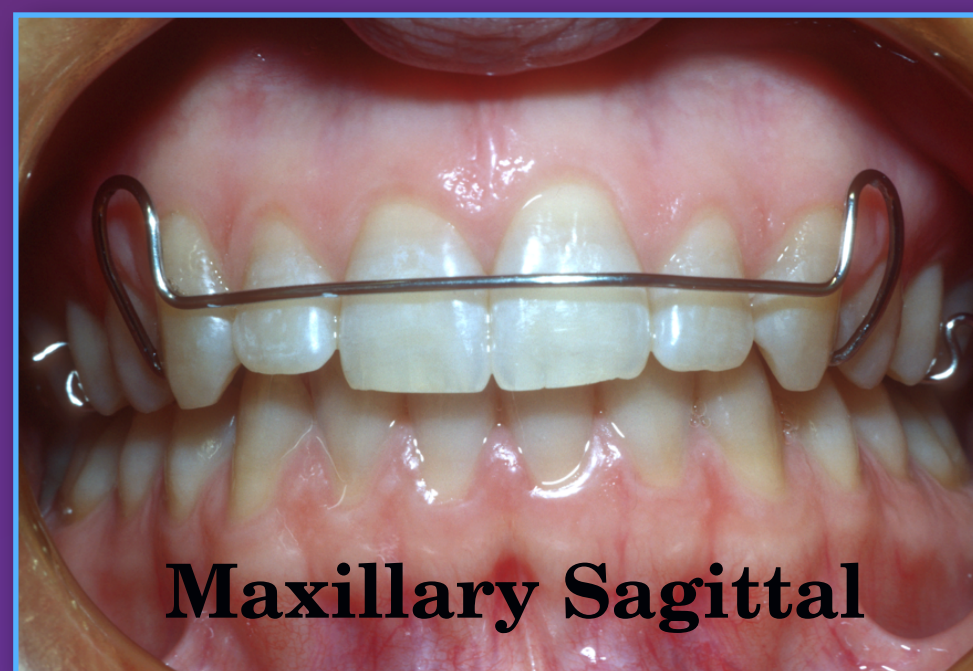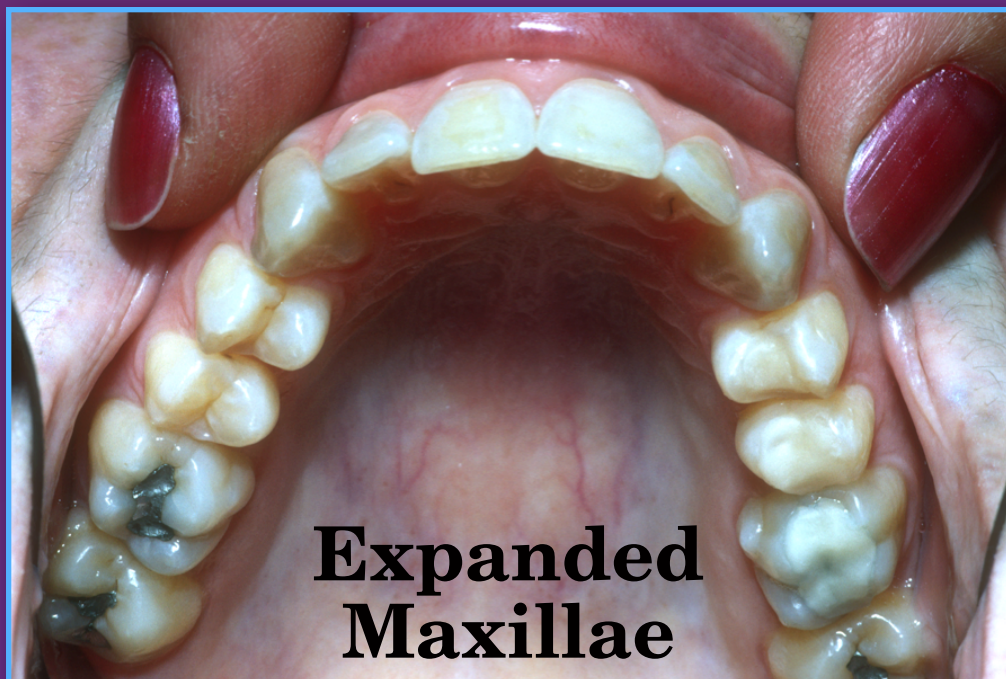Dx: Dental/Cranial distortions, canted and narrow maxillae

Petit mal seizures are brief (three to 30 seconds) with loss of consciousness and may consist of only a short cessation of physical movement and loss of attention.

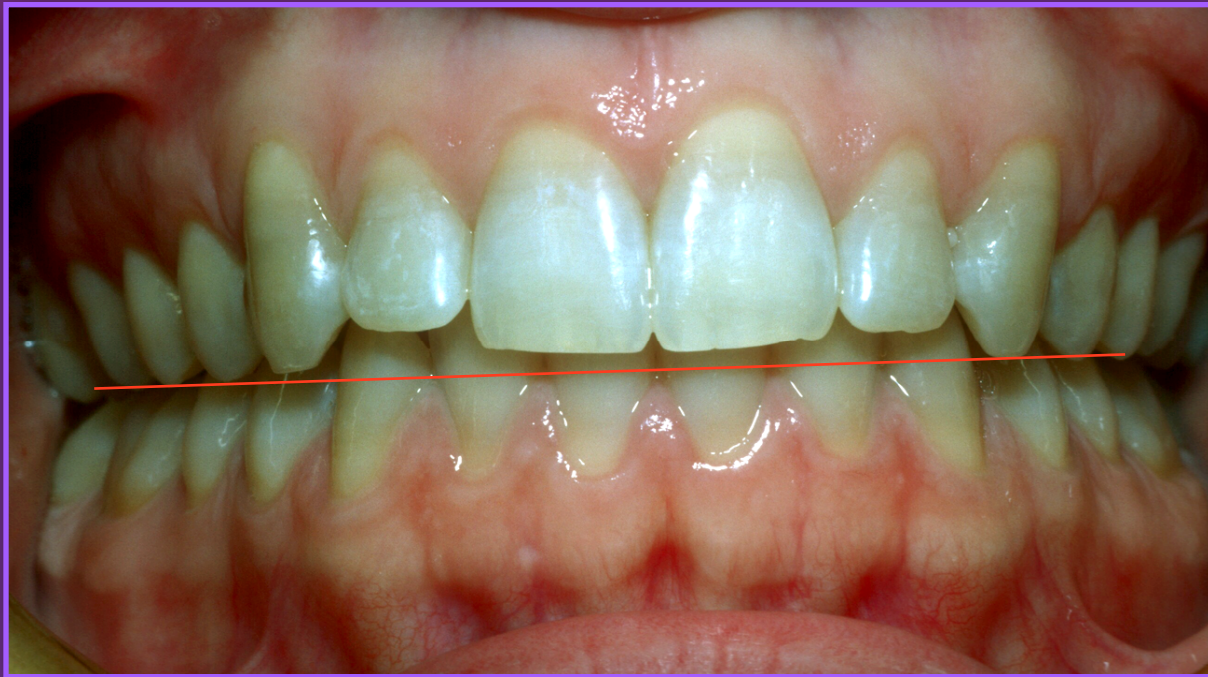Tx: Dental orthopedics/orthodontics to correct cranial lesions

Results: Complete resolution of petite mal seizures and headaches.

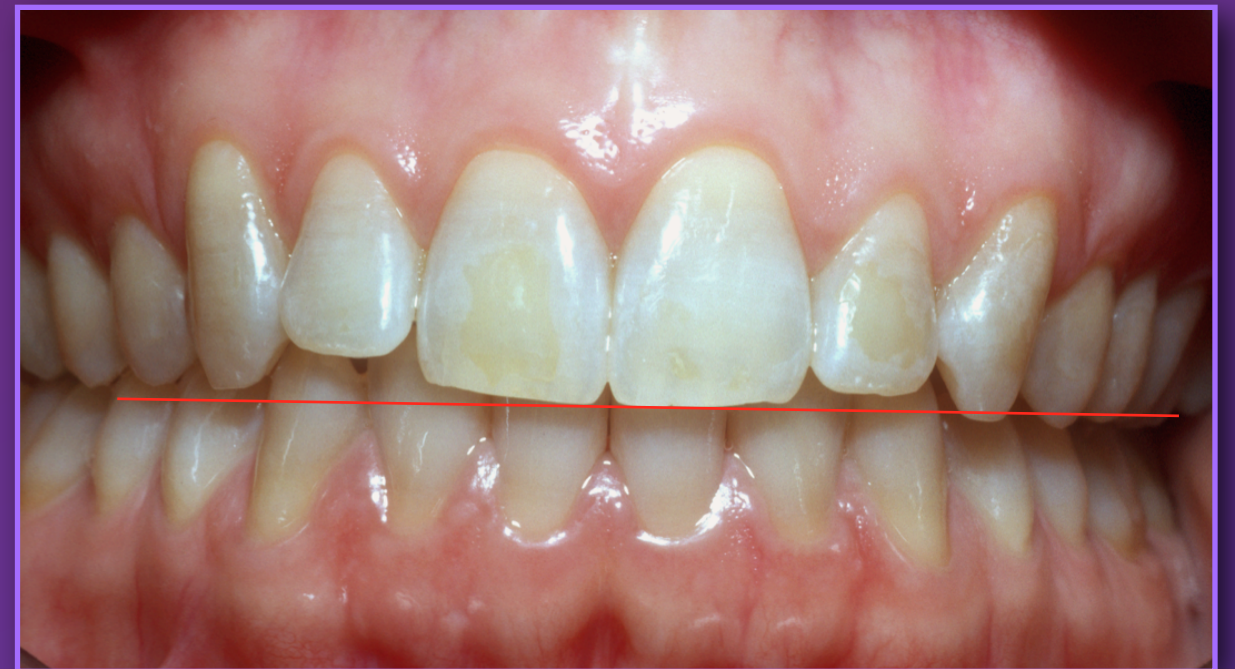Dental Seizure Connection



Dental Seizure Connection

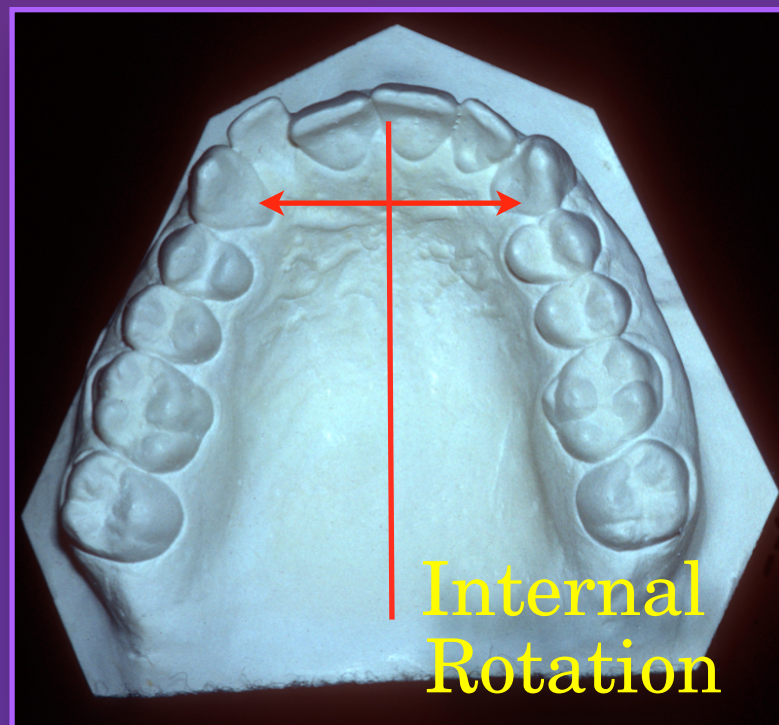


Pre-Tx

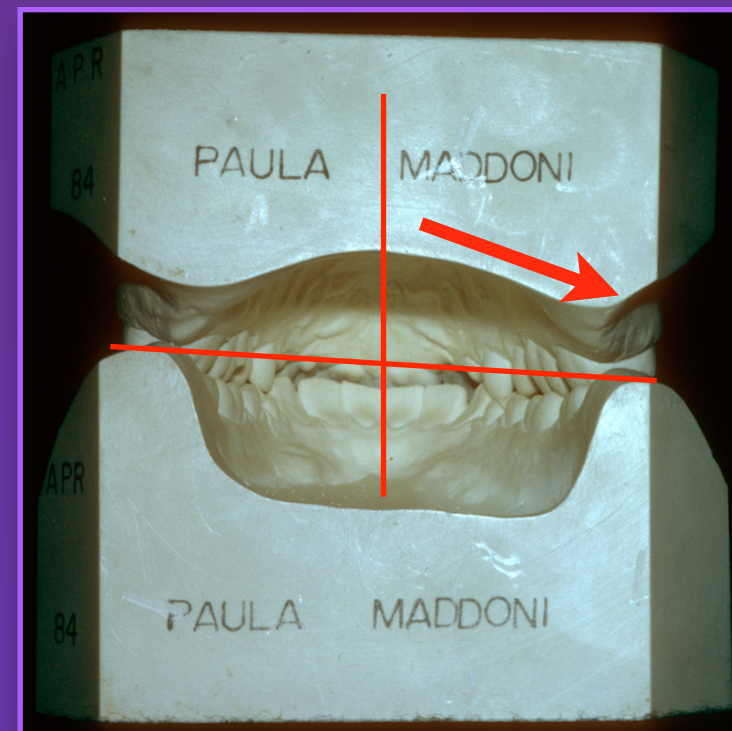


Post-Tx

Anterior
narrowing of
pre-maxillae



Internal
Rotation



Right half of
maxillae is
externally
rotated

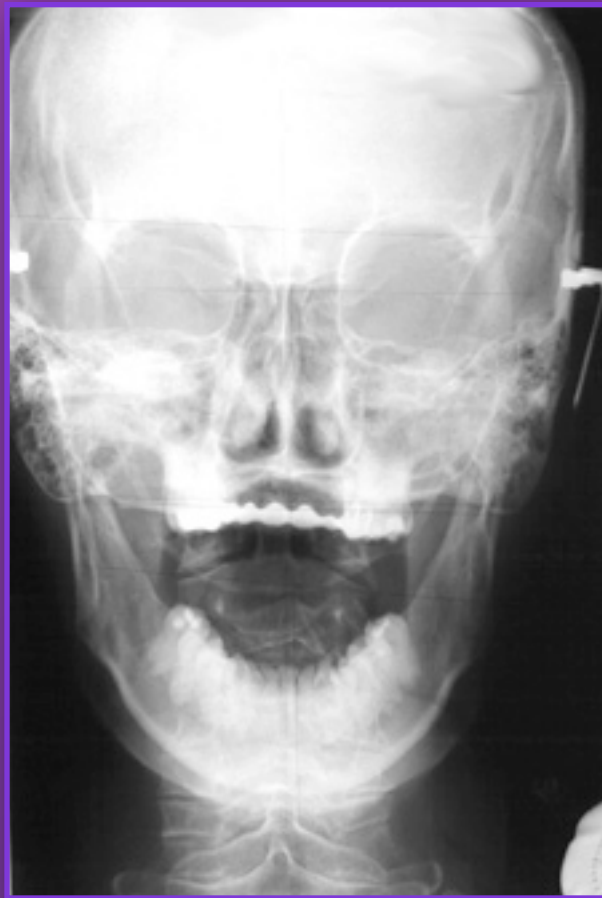DENTAL FIXED BRIDGEWORK INDUCED HEADACHES

Functional Considerations

Cranial/Dental Connection

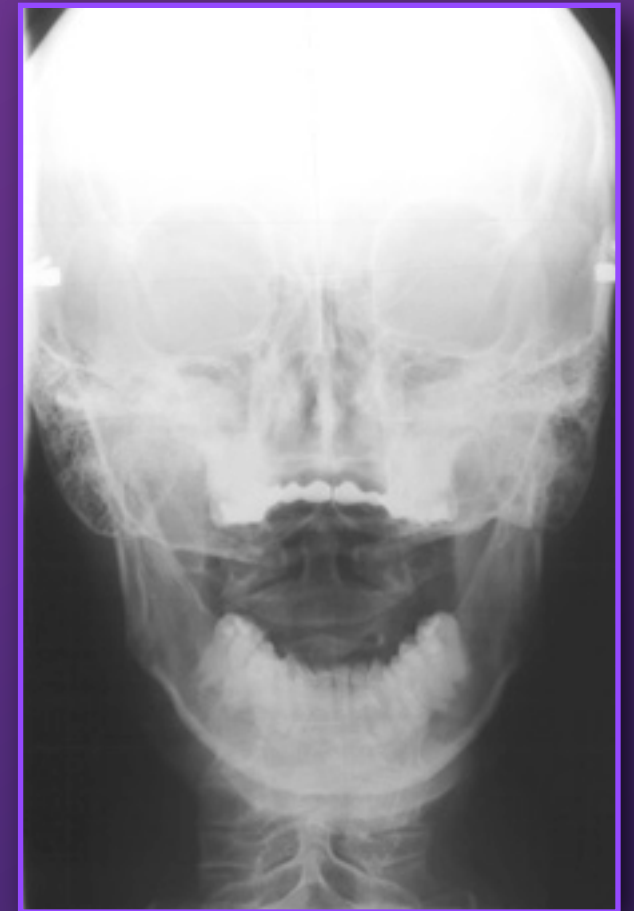20 years Facial Pain

- Maxillary transverse plane
- Horizontal plane of atlas
- Transverse plane of orbits
- Palatal arch shape
- Position of nares
- Transverse plane of mastoids
- Spinous process of C-3



10 unit fixed bridge

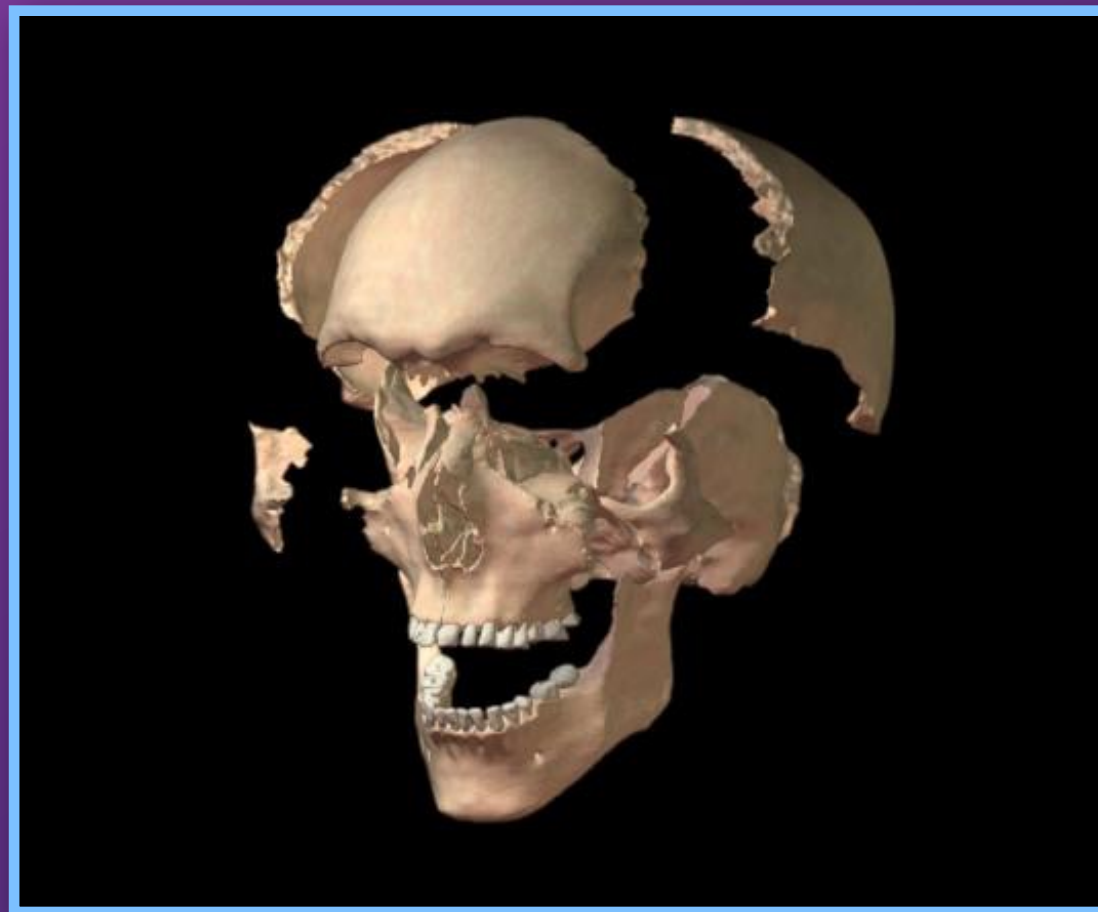Tx: cut mid-line and cranial
manipulation



One hour later

HUMAN SKULL

The 22 bones of the skull are joined by sutures, which act as contraction expansion joints. When dentists construct ridged appliances like cast bridgework that crosses the mid-line of the palate (roof of the mouth), it prevents the normal motion of the skull. Violation of this functional anatomy is often the cause for pain and other neurological symptoms.





Julie Sieber

42-year-old

14 units C & B: splinted maxillary arch

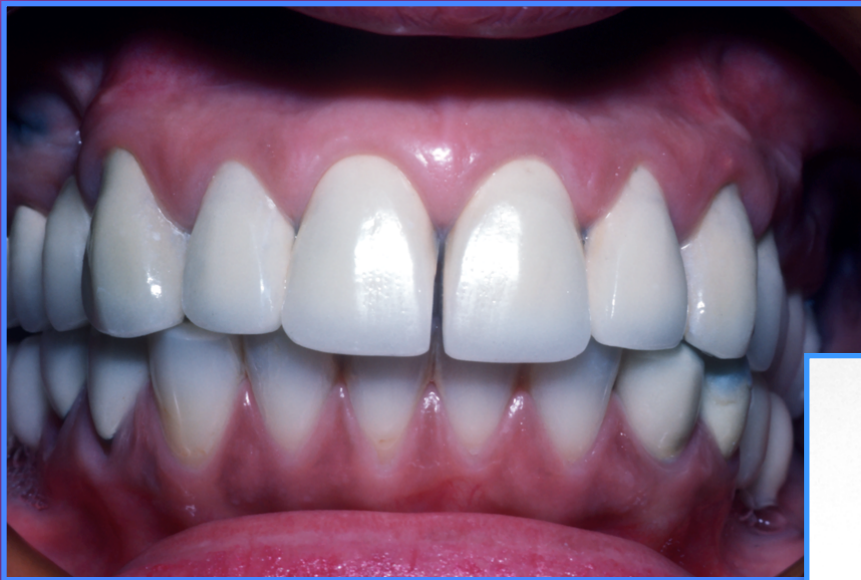Case restored by a Board Certified Prosthodontist

First five major symptoms started immediately after the bridge was inserted.

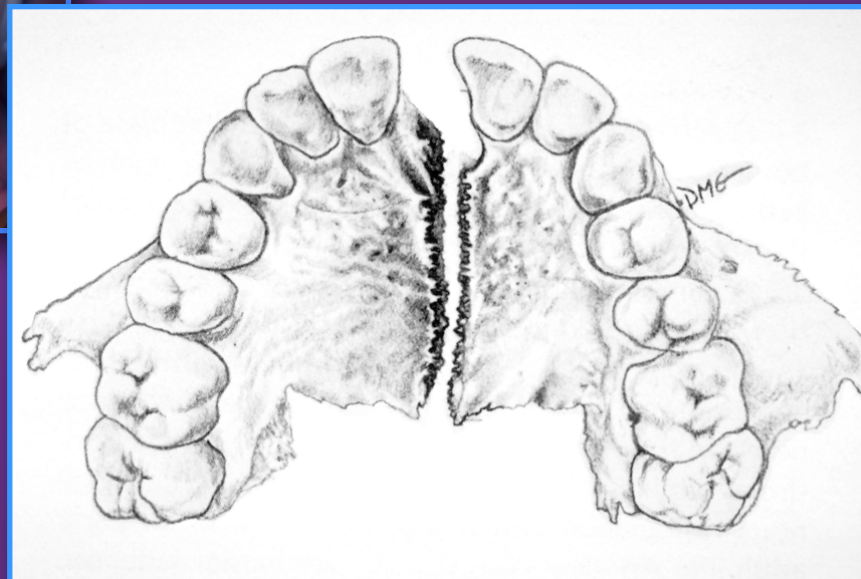
1. Constant hat band headache
2. Facial and cranial tightness
3. Generalized feeling of stress and irritability
4. Upper cervical neck pains
5. Limited right and left rotation of the head
6. Disequilibrium - progressive
7. Generalized chronic fatigue - progressive
8. Generalized muscle weakness - progressive
9. Paresthesia of the arms and legs - progressive

Functional Considerations

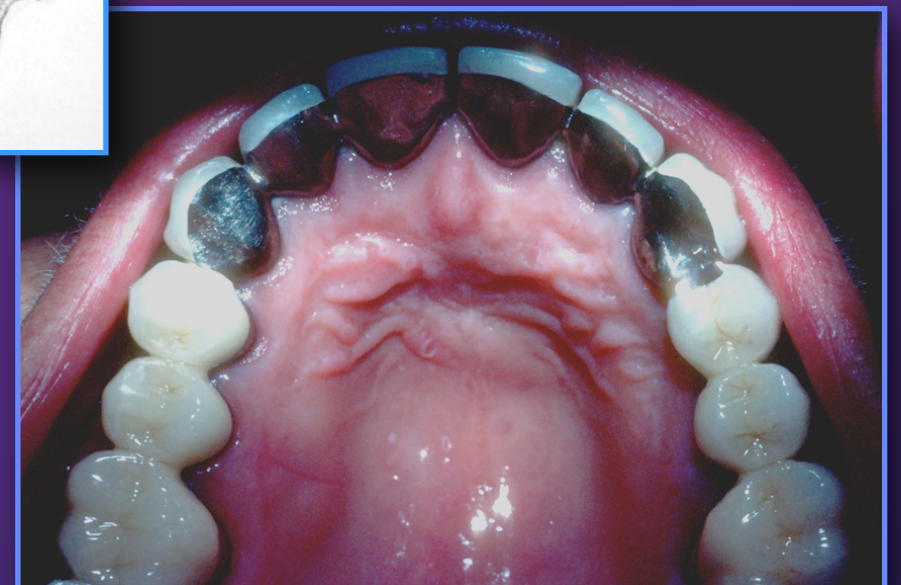
Dental/Somatic Connection



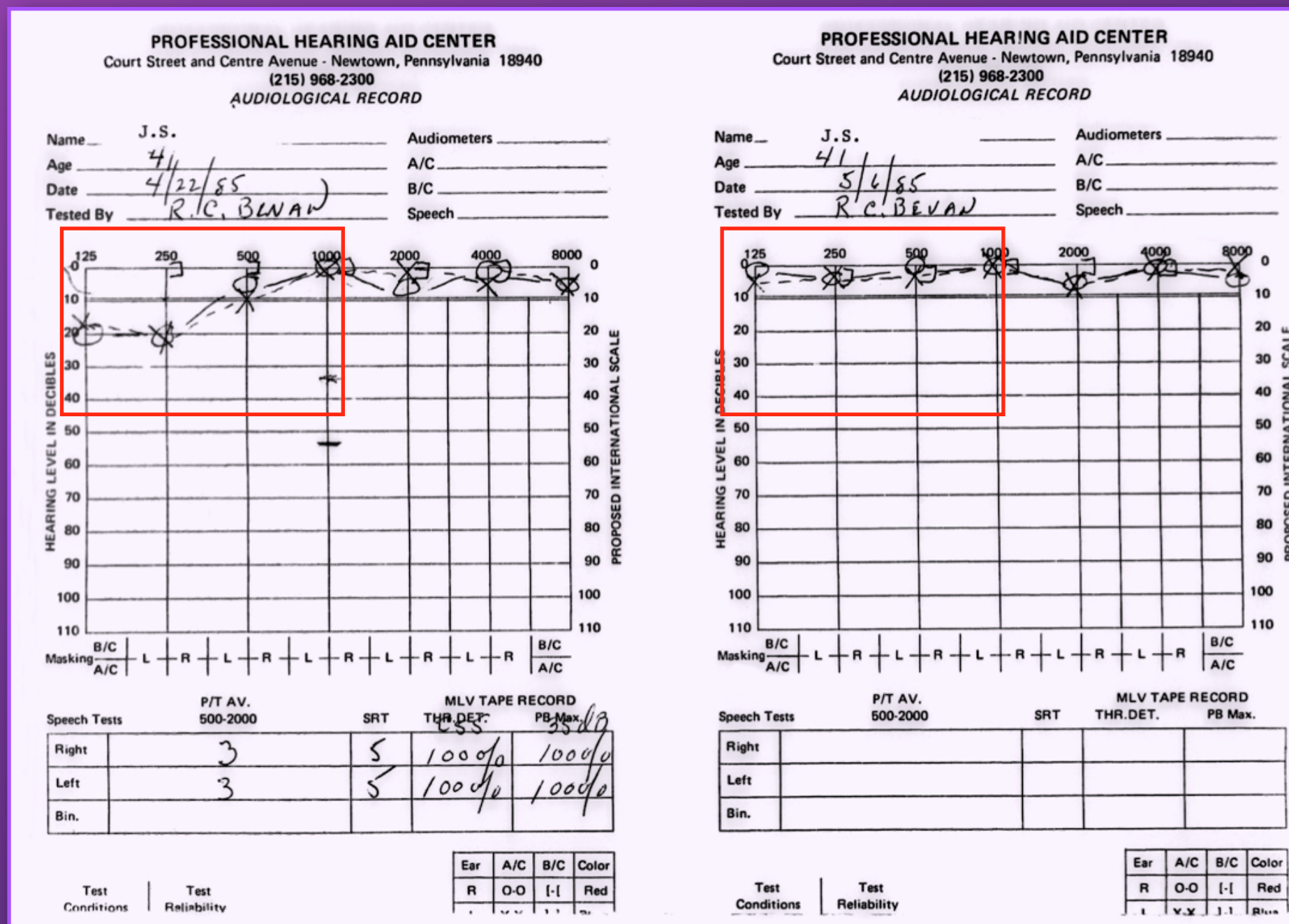
14 unit rigid connector



Normal cranial motion prevented



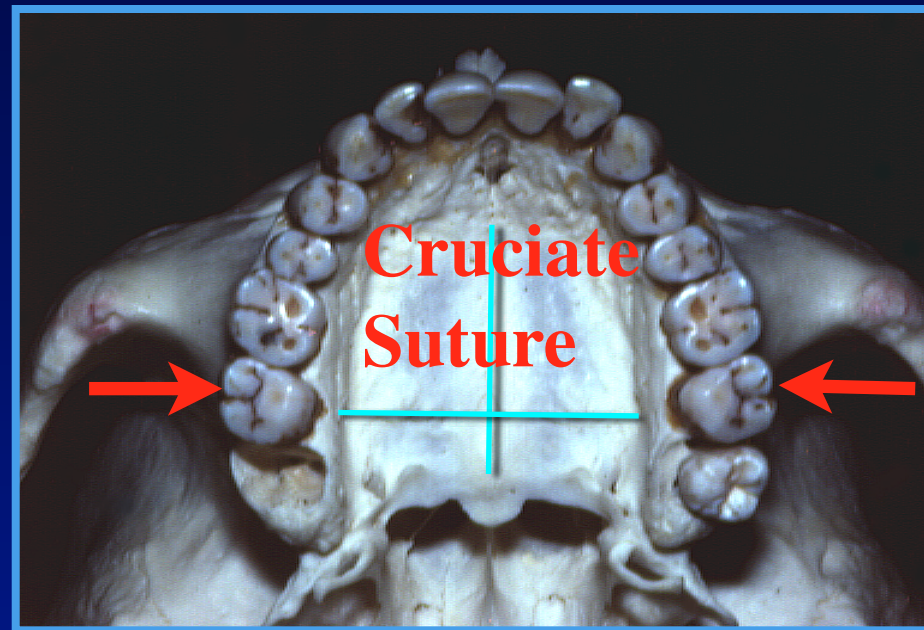
Dental/Somatic Connection



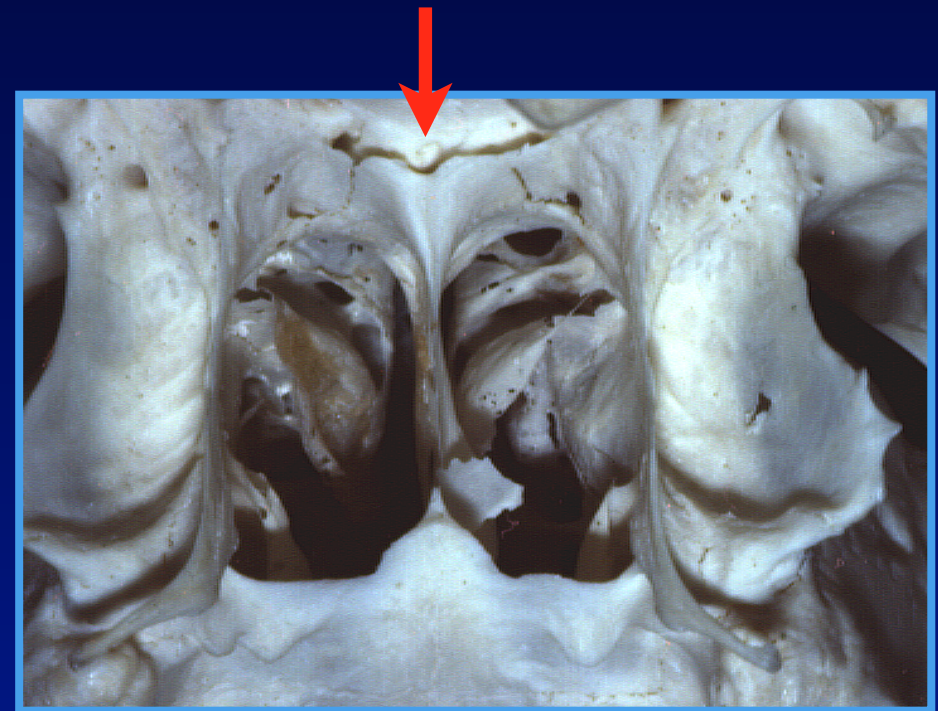Audiometric tests documented an increase of 20 decibels in the 125 and 250 frequency range.

**EXTRACTION
RETRACTION
ORTHODONTICS CAN
CAUSE PAIN**

Cranial/Dental Connection




Maxillae directly articulates with ten other bones




Vomer directly articulates with the sphenoid

Robert Ellis



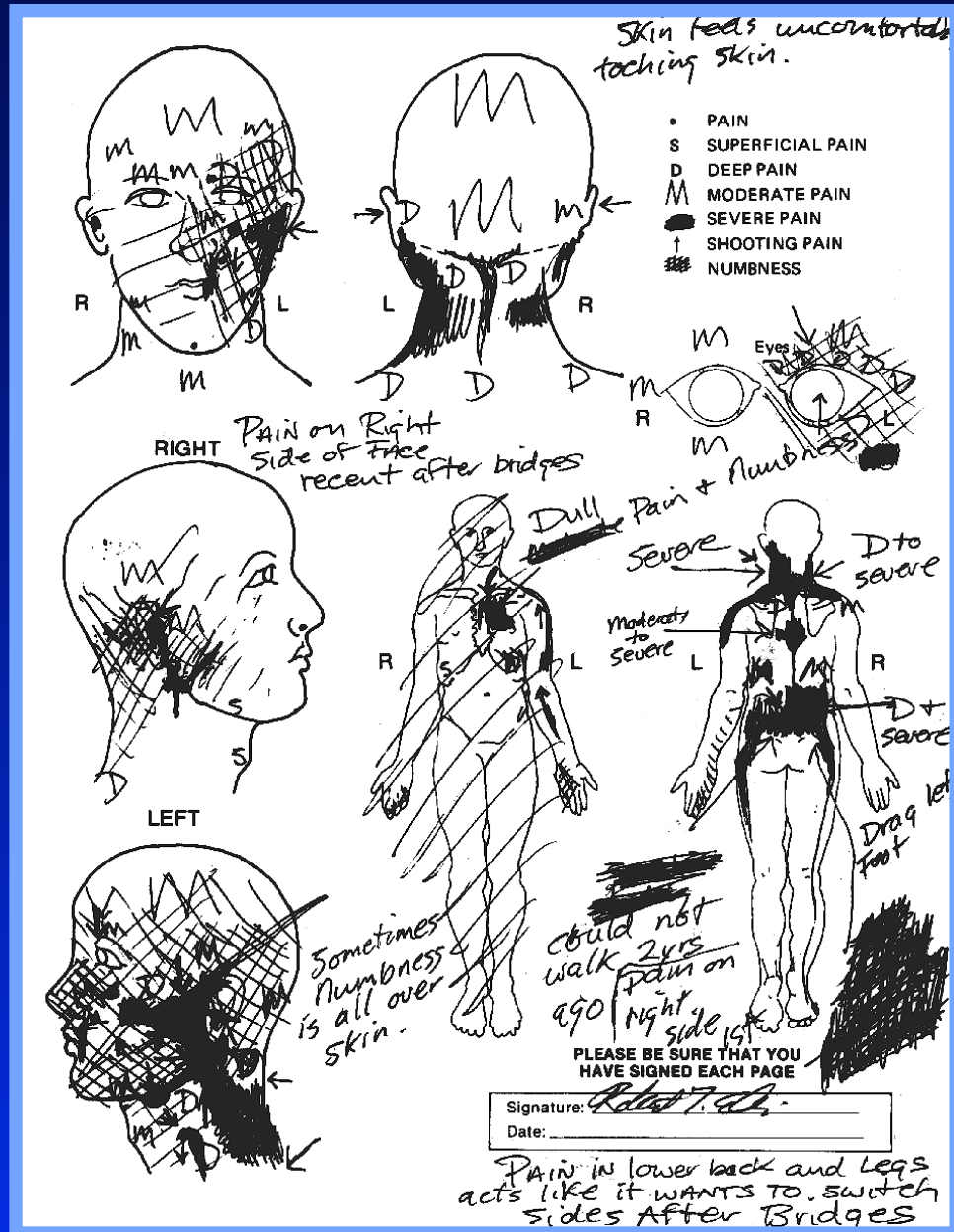
Sympathetic Dominant

**6 Months
ALF
Treatment
and
Nutritional
Support**



Balanced ANS

TMJ Diagnostic Record

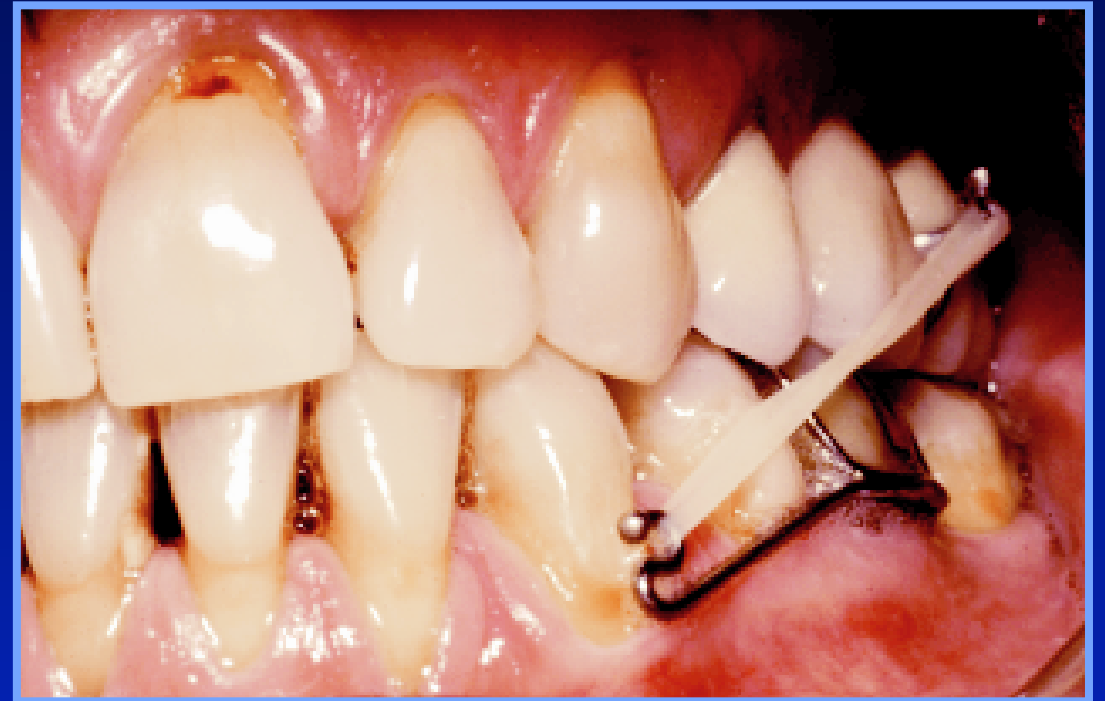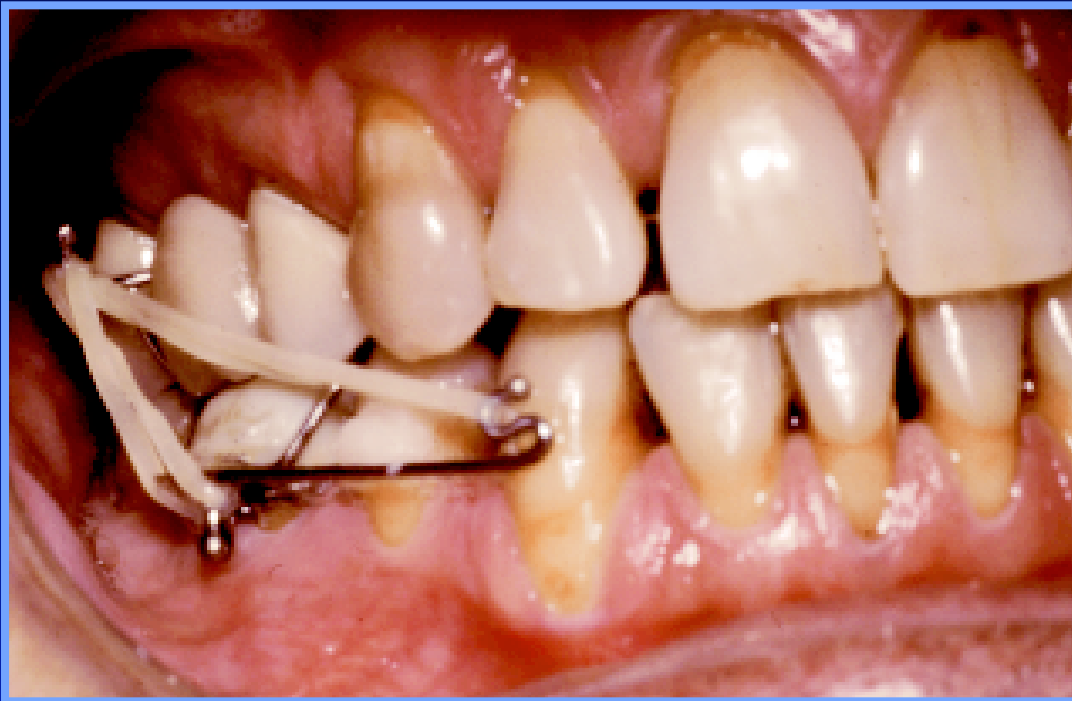


Robert Ellis

Highlights

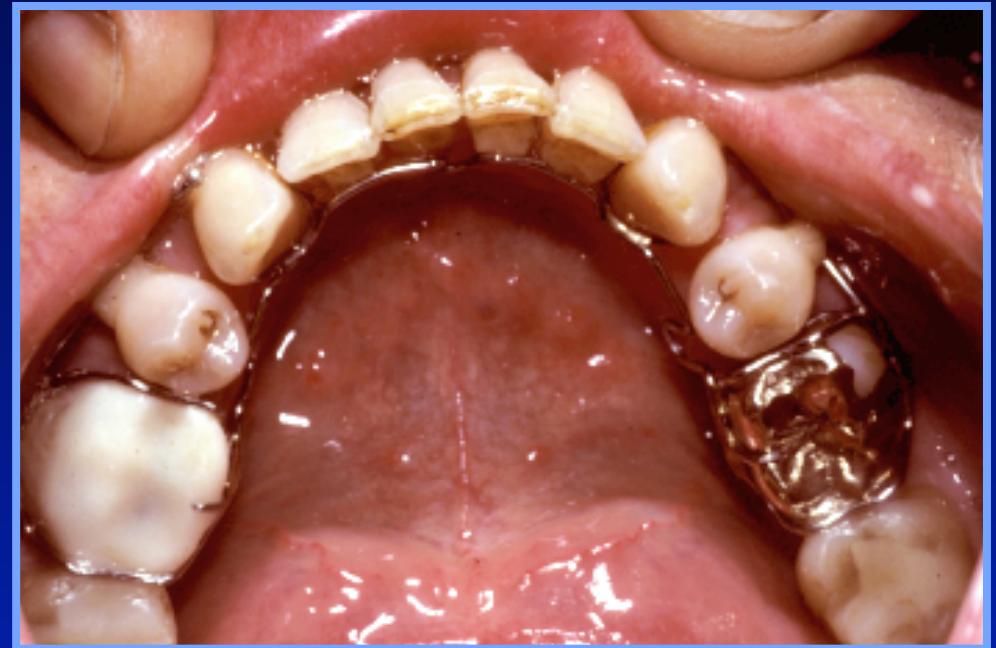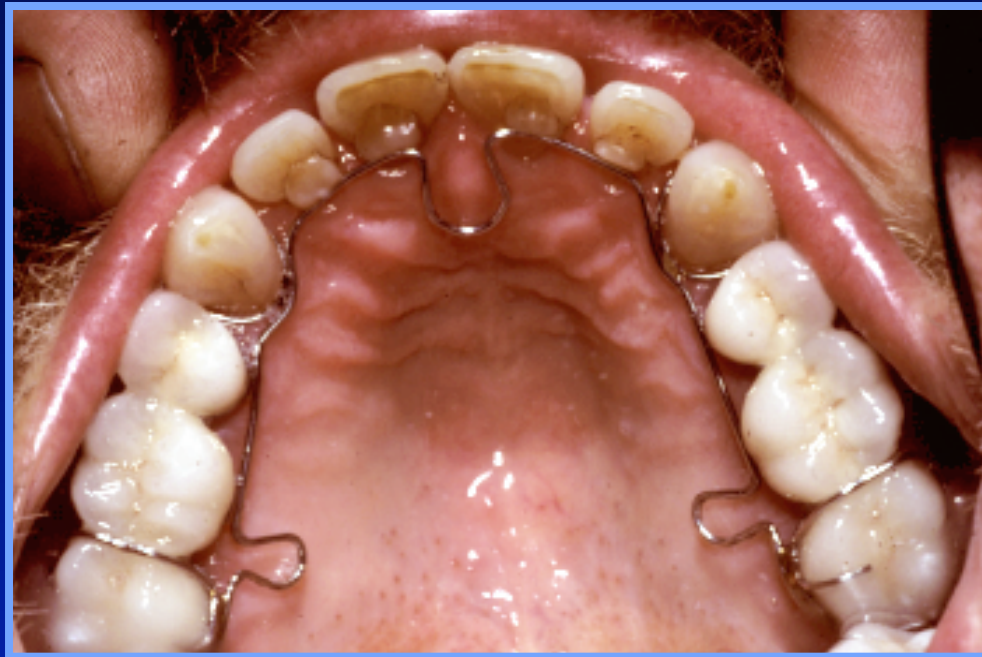- Day braces placed patient (age 12yrs) became dysfunctional: lost coordination and mental acuity.
- Pain on right side of face occurred soon after two three unit maxillary bridges placed.
- Following bridge insertion, pain in lower back and legs felt like it wanted to switch sides.
- Could not walk two years ago.
- Moderate to severe pain and numbness over entire body.

Robert Ellis



Custom designed ALF appliances were used to disimpact the maxillae and vertical elastics used to correct a high right sphenoid.


Robert Ellis



Treatment objectives were to correct the cranial lesions, level and disimpact the maxillae.

**DEEP OVERBITE
INDUCED FORWARD
HEAD POSTURE,
HEADACHES AND LOW
BACK PAIN**

Hunter Wooleyhan



Age: 15-year-old

Date: 3/17/94

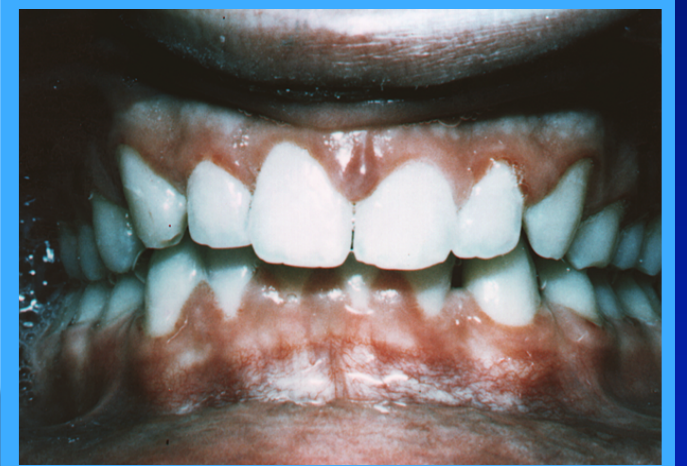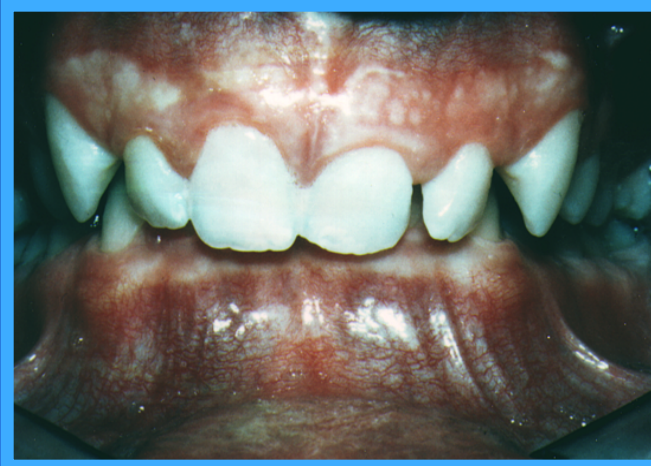Occupation: Student

Chief Complaints:

1. Low back pain
2. Frequent headaches
3. Deep overbite
4. Forward head posture

Cranial / Dental Correction

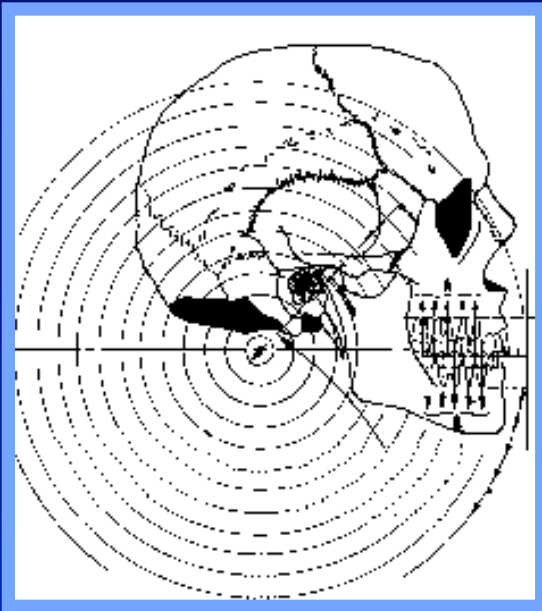
**A deep overbite closes the airway
resulting in forward head posture**



**Correcting the deep overbite automatically
corrected his severe forward head posture.**

Dental/Chiropractic Connection

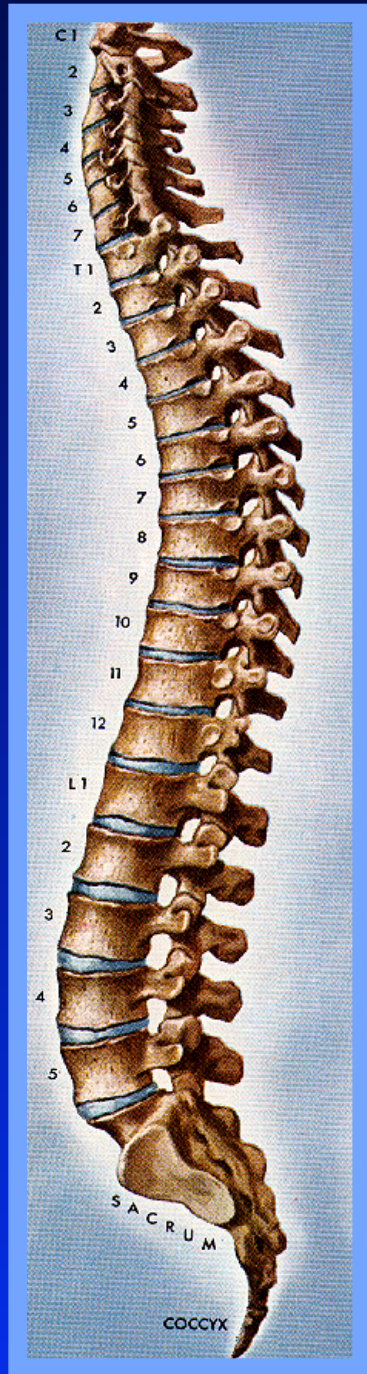
Quadrant Theorem



Casey Guzay

The center of rotation of the mandible is the odontoid process. All distortions of the occlusion will directly affect function of the cranial bones, dural membrane system, cervical, thoracic, lumbar, sacrum, pelvis and associated structures.

Dental - Chiropractic Connection



All vertebrae with the exception of the atlas have a three point contact. The third point of the atlas tripod is the occlusion. A balanced bite helps stabilize the atlas, cranial bones, dural membrane system, spine, sacrum and pelvic structures.

DENTAL CRANIAL DISTORTIONS INDUCES THORACIC OUTLET SYNDROME

Thoracic Outlet /Dental Connection



Patient: Beverly Speck

Age: 35-year-old

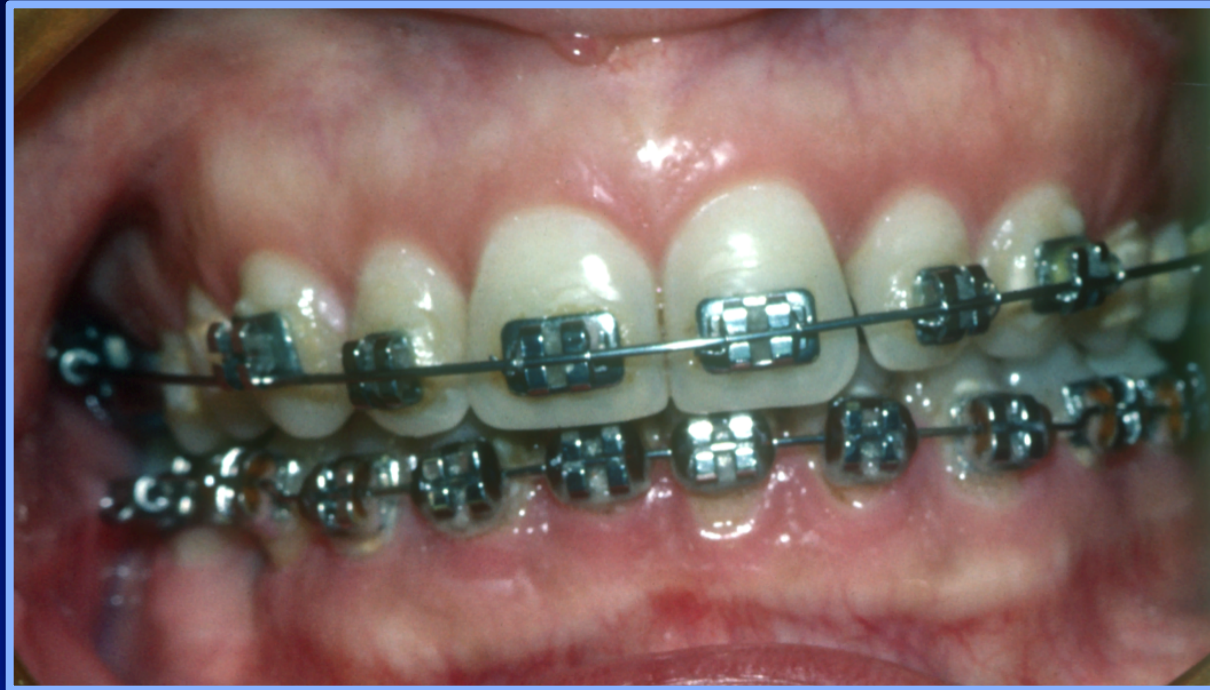Date: April 1986

Patient unable to work for one full year.

Chief Complaints:

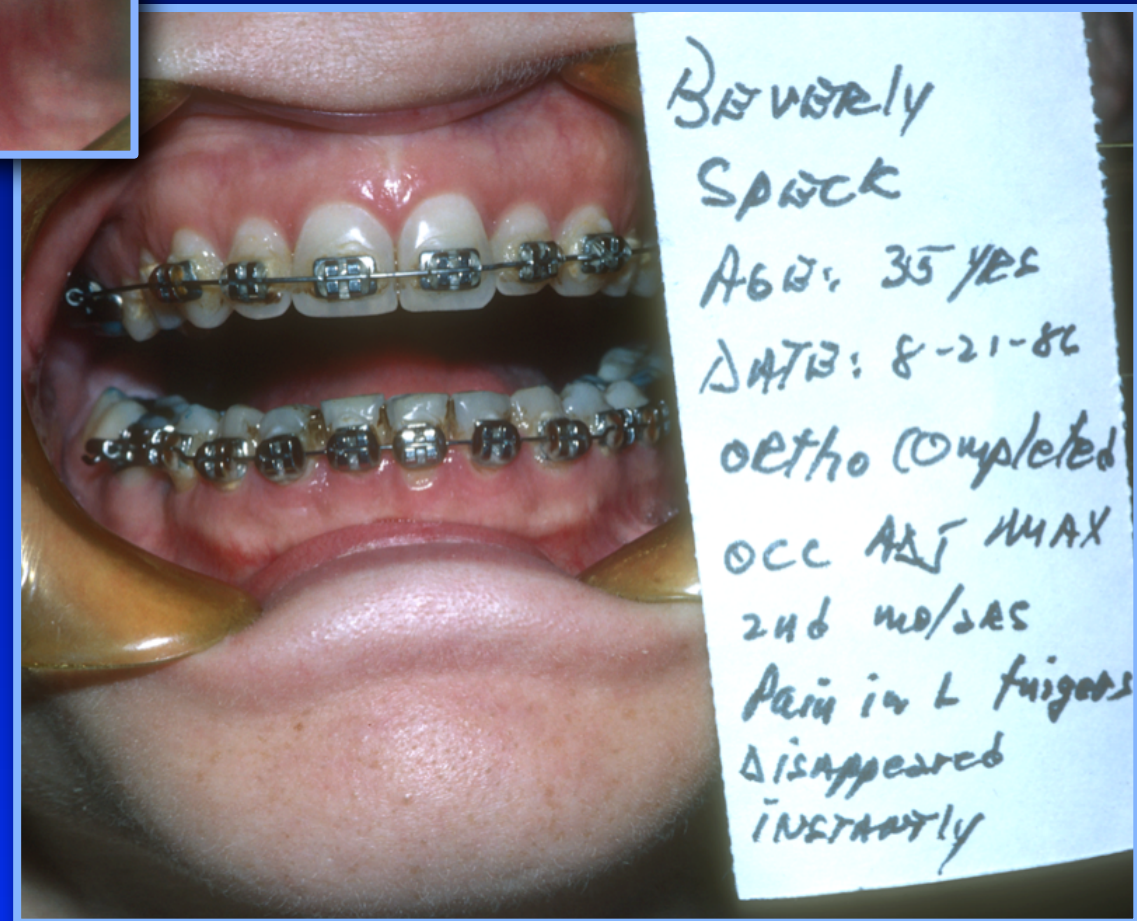
1. Complete numbness in left arm.
2. Partial numbness and tingling in the R & L legs.
3. Severe migraine headaches.
4. Weakness in left arm and leg.

Thoracic Outlet /Dental Connection



4 months since previous visit

Left arm and leg weakness
resolved in three weeks.



Thoracic Outlet /Dental Connection



1987



2020

Patient has been virtually pain free of
Thoracic Outlet Syndrome and headaches for 34 years.

FAULTY ORTHODONTICS INDUCED PAIN

Beverly Marsh



Age: 27-year-old

Date: 2004

Occupation: School teacher

Chief Complaints:

1. Severe facial pain. Applied hot compresses on face to ease the pain before bedtime
2. Difficulty talking
3. Neck and shoulder pain
4. TMJ pain

5. Headaches

6. Unable to sleep through the night because of pain

7. Fatigue

Dental History: All symptoms started after conventional orthodontics were completed at age 17 (1994). Fifty doctors were seen during the 10 year period.

Beverly Marsh



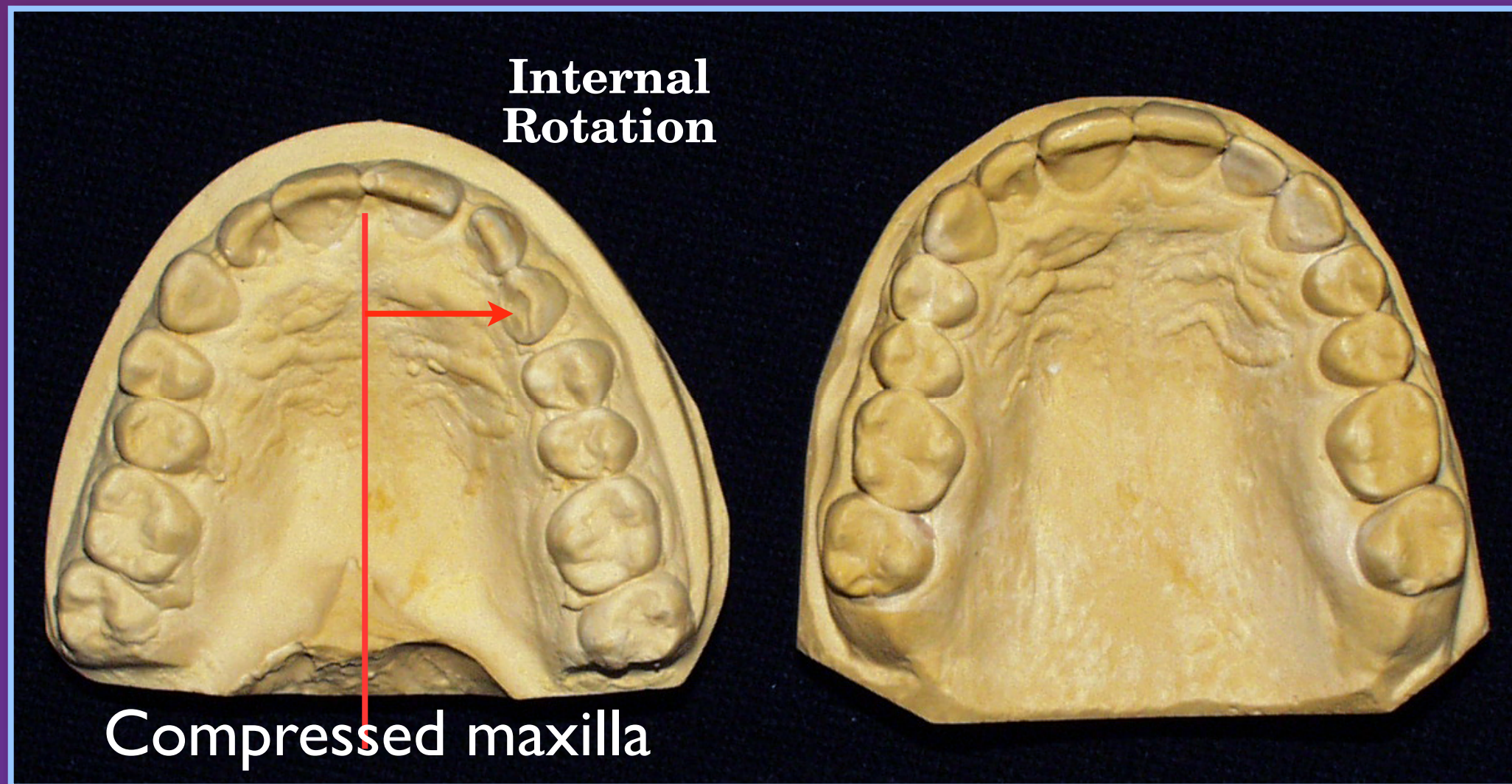
Pre-Tx

ALF placed
and adjusted
to balance the
four cranial
indicators



24 hours post ALF
insertion

Beverly Marsh

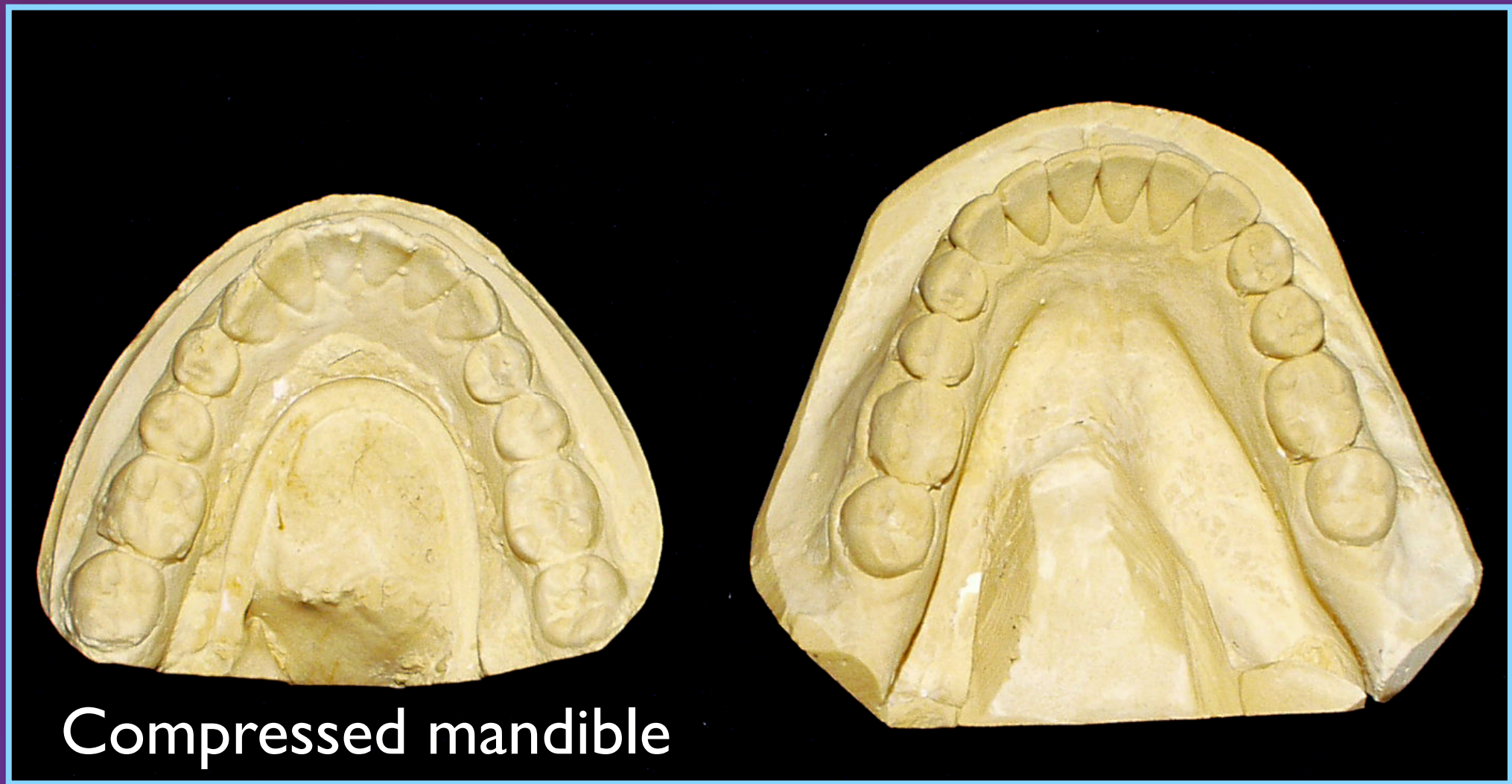

Pre-Tx

Post-Tx

Cranial base was expanded and corrected 3-dimensionally.

Beverly Marsh



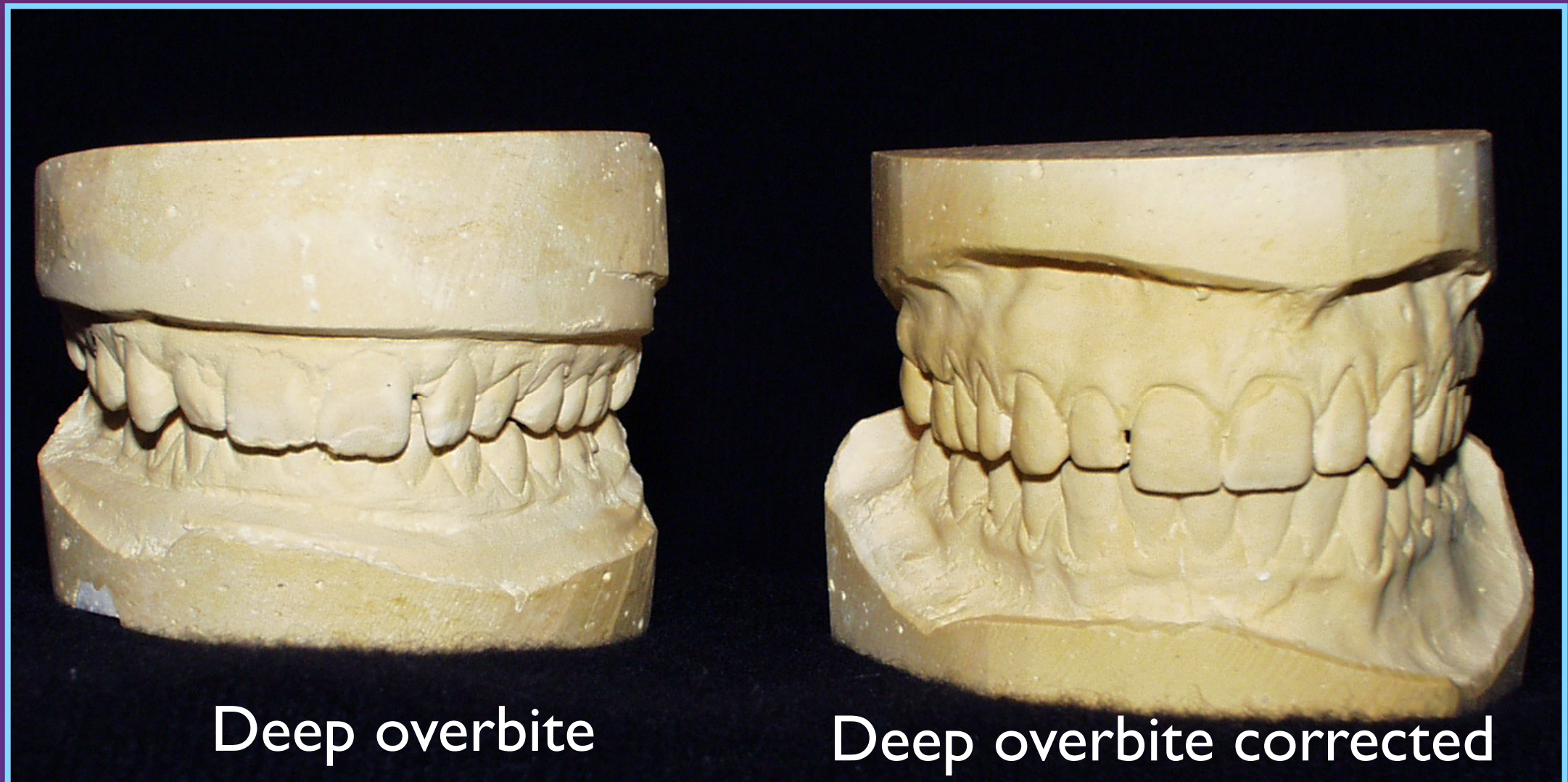
Compressed mandible

Pre-Tx

Post-Tx

Mandibular arch was expanded to fit the maxillary template.

Beverly Marsh



Deep overbite

Pre-Tx

Deep overbite corrected

Post-Tx

The vertical, transverse and sagittal planes
were brought into balance.

MERCURY TOXICITY INDUCED BIPOLAR DISORDER

Dental Bipolar Connection

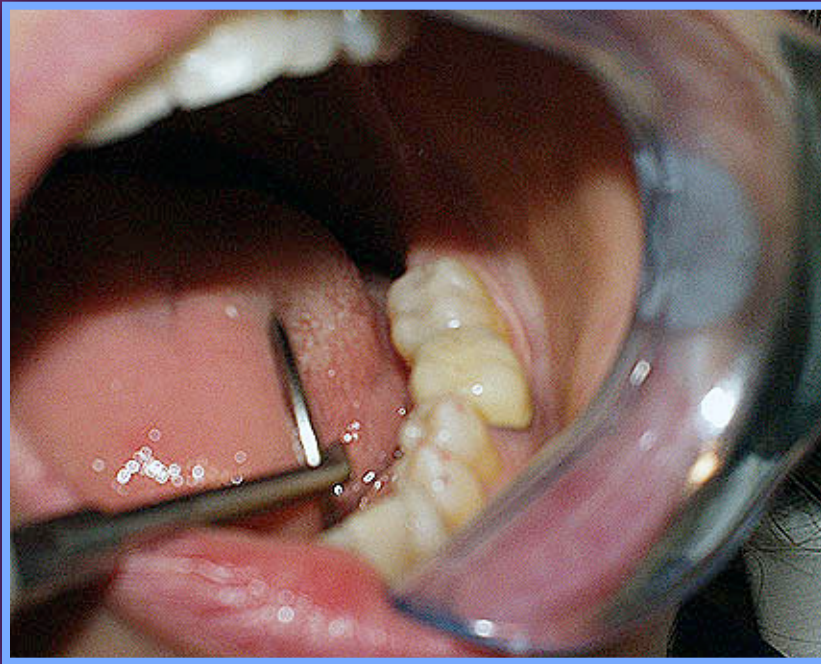
Case Study: H.S.

- 29 years suffered Manic Depression.
- Father was a dentist and restored son's caries with mercury fillings.
- Medicated with lithium, Depakote and Zoloft
- Mercury fillings removed by a biological dentist
- One year detoxification with oral chelators
- Totally free of all bipolar symptoms for over two years

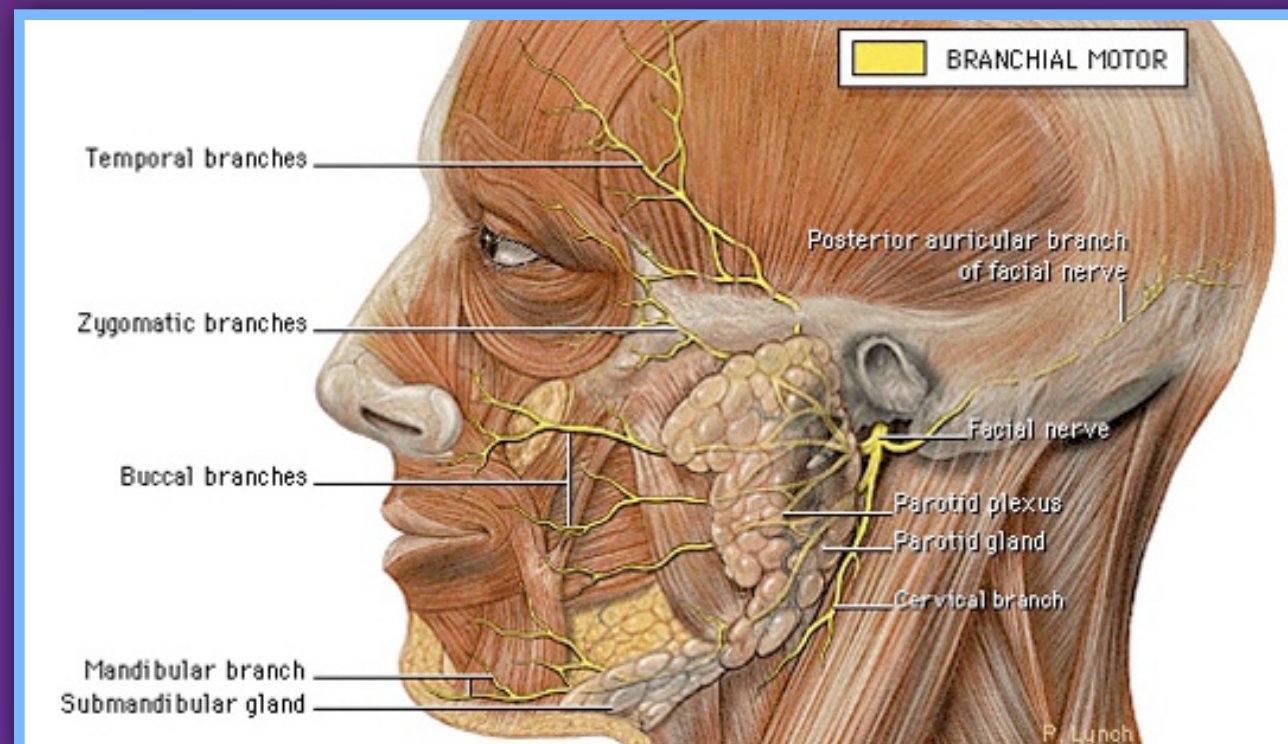
Key factors: mercury migrates to the thyroid (depression) and brain (mania)

Father learned a heart wrenching lesson and has discontinued the use of mercury in his practice.

DENTAL CRANIAL FOOT CONNECTION

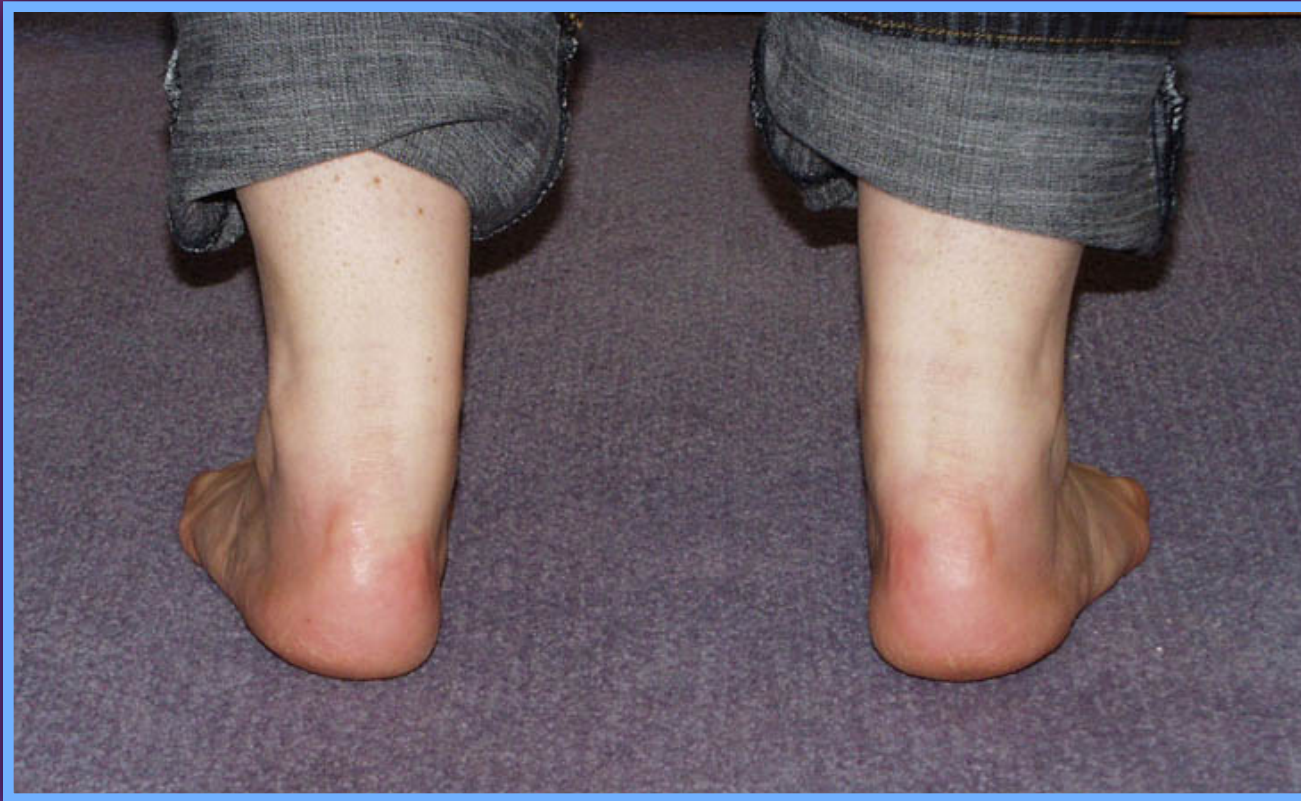

Ten years of right side facial pain defied all treatment attempts of resolution. Underlying problem was occlusal cranial distortions, which torqued the dura and created an imbalance of the sutures and right side masseter muscle. The distortion **descended** causing foot pronation.



The right side facial pain followed the exact distribution of the five branches of the facial nerve.

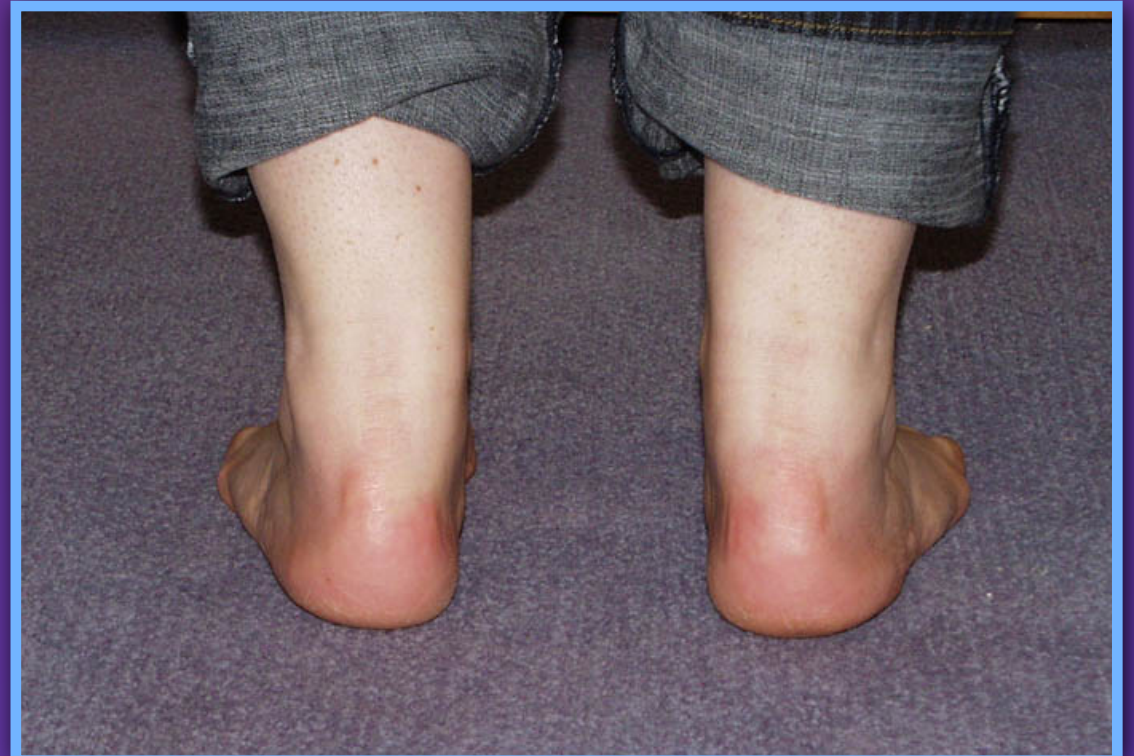DENTAL CRANIAL FOOT CONNECTION



The pronation of feet dramatically improved following Occlusal Cranial Balancing with one shim.

Descending lesion

One and a half hours of treatment.



**FAULTY CROWN
DESIGN
INDUCED LOWER BACK
PAIN FOR EIGHT
YEARS**

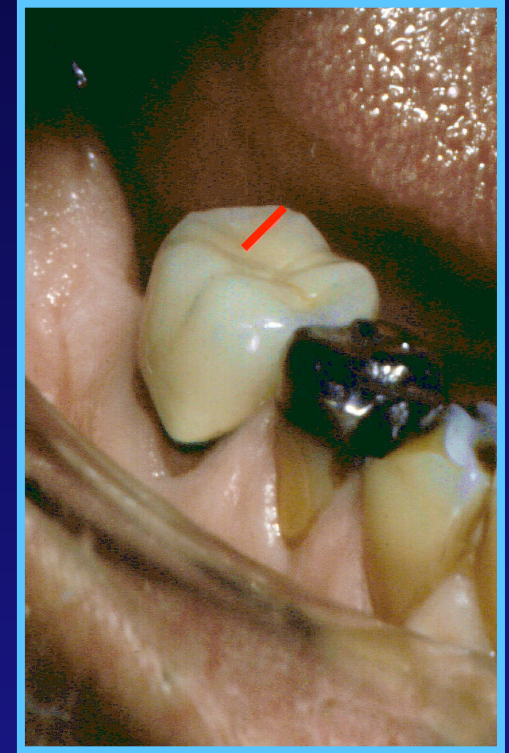
Dental Low Back Pain Connection



Age: 62-year-old

Date: December 5, 2000

Occupation: Engineer



Chief Complaints:

1. Constant low back pain for 8 years - Started day the lower right first molar crown was cemented.
2. Tx : Neuro Occlusal Adjustment - Low back pain disappeared immediately. Has been pain free since 2000.

Drug Induced Vertigo

Drug Induced Vertigo



In 2017, ninety year old Carmen Mazzuca was given Ciprodex to treat a left ear infection. Within 10 minutes after taking the medication he developed severe vertigo. For over 1 year Carmen sought medical help from top specialists with no results.

**Vertigo totally Resolved immediately With
one dose of a Custom Homeopathic
Remedy**



*“It ain't what you don't know that gets you into
trouble.*

It's what you know for sure that just ain't so!”

Mark Twain

Visit My Websites

- **www.icnr.com**: 160 case studies and many articles
- **www.ghsdoc.live**: numerous video lectures and podcast interviews
- **www.teslaenergy-tec.com**: vibrationally infused remedies and the Tesla Energy Card

Please tune into our podcasts. Listings
for upcoming presentations on
ghsdoc.live